

# Tendon Graft Reconstruction of Extensor Hood Deficits With Subluxation

Leo M. Rozmaryn, MD, Rockville, MD

Injuries to the radial or ulnar sagittal bands at the metacarpophalangeal (MP) joint may result from open or closed injuries to the dorsum of the hand. Closed avulsion injuries may occur as a result of a direct blow or from forced flexion or extension to the MP joint. Typically, the radial sagittal bands are involved and the central slip subluxes ulnarly into the adjacent groove. If the deficit is severe, the central slip remains in the trough, severely compromising the ability to extend the MP joint. In addition, ulnar deviation of the digit may result, and overpull of the central slip may cause a swan neck deformity. In most cases there is sufficient adjacent tendon material to repair and reconstruct the defect. If it cannot be repaired reliably primarily,<sup>1</sup> then juncturae tendinum<sup>2</sup> or segments of the extensor hood<sup>3</sup> can be threaded to an adjacent radial collateral ligament or lumbrical tendon to shift the vector forces about the central slip tendon so that it glides centrally. The following is a technique for the centralization of the extrinsic extensor tendon in those cases in which no sagittal band exists on either the radial or ulnar side and no juncturae exists nearby, and the quality of the tendon itself is questionable so that dividing it would attenuate it unnecessarily.

## Case Report

A 62-year-old woman was treated for a severe *Mycobacterium marinum* infection in her left index finger 4 years before presentation. She underwent seven debridements, mainly on the dorsum of the digit, and, because of either the disease or the surgery, remained without any sagittal bands near the proximal phalanx. The extensor mechanism had receded into the groove between the index and middle metacarpals (Fig. 1). In addition, there was a 45° extensor lag at the MP joint and a swan neck deformity with 30° of hyperextension at the proximal interphalangeal (PIP) joint (Fig. 2). However, she was able to flex both the MP and the PIP joints to 90°.

Intraoperatively, the extensor mechanism was noted to have receded into the groove between the index and middle metacarpals. The central slip was markedly attenuated and the longitudinal division would render it virtually unusable (Fig. 1). Instead, the surgeon used a free tendon graft, using the palmaris divided into two equal segments. The radial and ulnar collateral ligaments were incised longitudinally at the metacarpal head. Two bone anchors were placed into the metacarpal head, one from each side (Fig. 3). Each was used to anchor a separate tendon loop that swung around the central slip and back. In this fashion, the central tendon became tethered to the midline at the level of metacarpal metaphysis, but was still able to glide. The grafts were placed at the junction of the metacarpal head and neck, and not further distally, so as not to impede MP extension (Fig. 4). Intraoperative passive movement of the finger revealed full gliding of

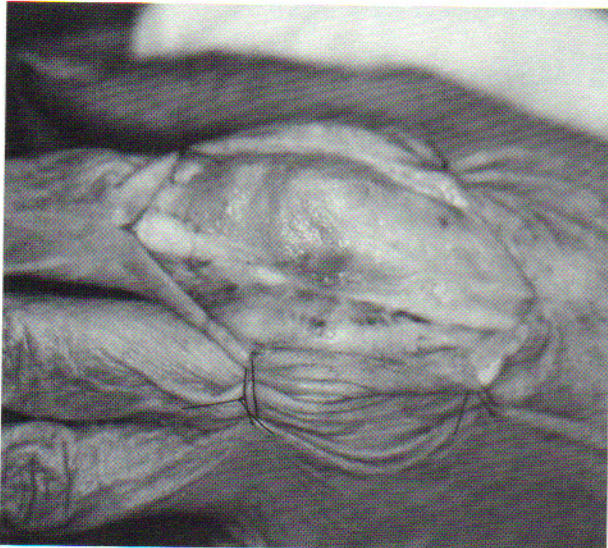---

From The Orthopaedic Center, P.A., Rockville, MD.

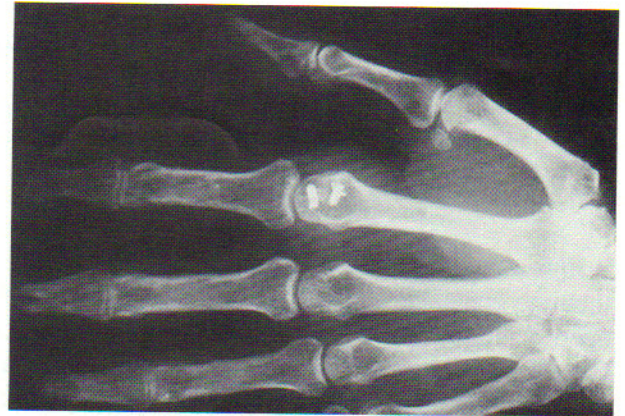Received for publication September 8, 1994; accepted in revised form February 20, 1995.

No benefits in any form have been or will be received from a commercial party related directly or indirectly to the subject of this article.

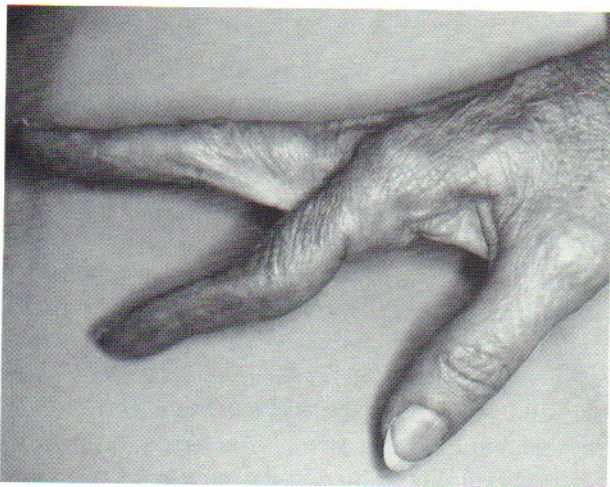Reprint requests: Leo M. Rozmaryn, MD, The Orthopaedic Center, P.A., 9711 Medical Center Drive, Suite 201, Rockville, MD 20859.



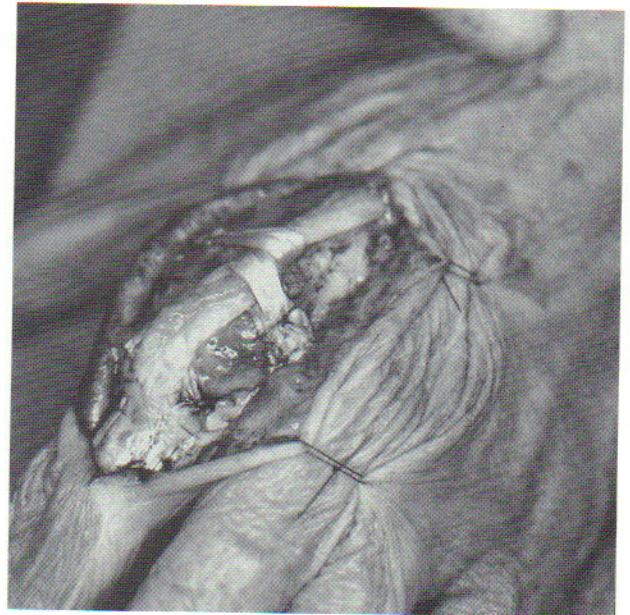**Figure 1.** Ulnar subluxation of the central slip of the extensor tendon with no sagittal band fibers in evidence.



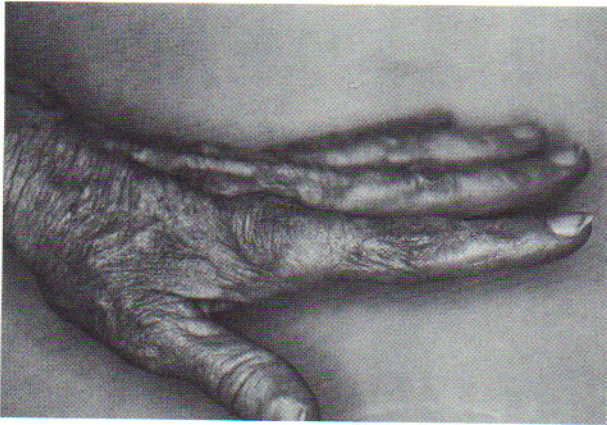
**Figure 3.** Postoperative anteroposterior view of the hand revealing the presence of the bone anchors in place.



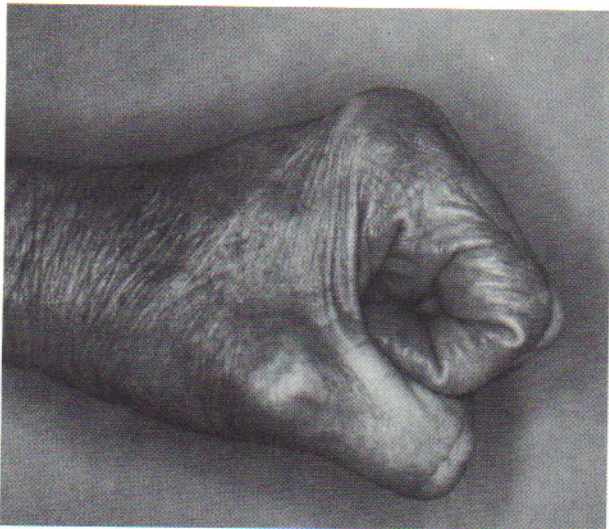**Figure 2.** Preoperative extensor lag at the metacarpophalangeal joint.



**Figure 4.** Intraoperative view revealing the free tendon grafts anchored securely into place with centralization of the extensor tendon.



**Figure 5.** Side view showing full extension of metacarpophalangeal joint 8 months after operation.



**Figure 6.** Eighty degrees of metacarpophalangeal joint flexion 8 months after operation.

the long extensor without tethering or subluxation. The graft was further secured by repairing the collateral ligaments.

To prevent adhesions with a resultant tenodesis effect of the long extensor at the metacarpal head, full active and passive motion of the MP joint was begun after 72 hours, protecting the repair with an extension assist orthosis that was worn for 6 weeks.<sup>4</sup> At 3 months, full extension of the MP joint resulted, with correction of the ulnar deviation and lessening of the swan neck deformity. At 8 months, the index finger regained a normal feel, with full active ability to extend the MP and the PIP joints (Fig. 5). Flexion of the MP joint was 80°, and of the PIP joints 90° (Fig. 6). This indicates that movement of the central long extensor tendon through the tendon graft loops indeed occurs. Clearly, suture anchors can be used to secure tendon grafts to bone, even when completely avascular but secure fixation is the key, so that early motion can be instituted.

### References

1. Kettlekamp DB, Flatt AE, Moulds R: Traumatic dislocation of the long finger extensor tendon: a clinical, anatomical, and biomechanical study. *J Bone Joint Surg* 1971;53A:229-240.
2. Wheeldon FT: Recurrent dislocation of extensor tendon. *J Bone Joint Surg* 1954;36B:612-617.
3. Carroll C IV, Moore JR, Weiland AJ: Posttraumatic ulnar subluxation of the extensor tendons: a reconstruction technique. *J Hand Surg* 1987;12A:227-231.
4. Chow JA, Dovel S, Thomas LJ, Callahan D: Postoperative management of repair of extensor tendons of the hand: dynamic splinting vs. static splinting. *Orthop Trans* 1987;11:258-259.