

Metacarpophalangeal Arthroscopy: Technique and Indications

LEO M. ROZMARYN, M.D.

*Clinical Assistant Professor of Orthopaedic Surgery
Georgetown University, Washington DC, U.S.A.*

KATHY LAMOTT, R.N., C.N.O.R.

PATRICIA CRAWFORD R.N., C.N.O.R.

*Special Coordinators for Outpatient Surgery
Shady Grove Adventist Hospital
Rockville, Maryland, U.S.A.*

■ HISTORICAL PERSPECTIVE

Although arthroscopy has gained universal acceptance in the diagnosis and treatment of major joint disorders, relatively little focus has been directed to the practicality of using these techniques for the metacarpophalangeal (MP) joint. Since 1979, there have been only six reports in the literature describing these methods.

Chen in 1979 (1) described MP joint arthroscopy in a rheumatoid patient with villous synovitis. He also described a "meniscus" encircling the articular surface of the proximal phalanx. In 1985, Vaupel and Andrews (5) described a case of a professional golfer with a 1-year history of painful, chronic synovitis and chondromalacia in the MP joint of the thumb. The patient underwent an arthroscopic synovectomy and chondroplasty. Postoperatively, the patient experienced a marked diminution in pain and was able to return to competitive sports within 6 months. The patient was relatively pain-free at 20-month follow-up. In 1987, Wilkes (6) performed arthroscopic synovectomy on 13 joints in five patients with rheumatoid arthritis. These were noted to have synovitis in the radial and ulnar recesses and the dorsoproximal recess under the extensor tendon without joint subluxation or destruction. Most of the patients experienced early pain diminution. However, at 4 years, all symptoms returned. Thus, this technique was found to be useful in alleviating pain and inflammation over the short term but did nothing to alter the natural history of the disease at the MP joint. Declercq et al. (2) described a patient with

painful swelling and recurrent locking of the MP joints with loss of flexion and extension. Intraoperative findings included inflamed synovium, cartilage detachment, and osteochondral loose bodies. The presumptive diagnosis was hemochromatosis. Synovectomy and chondroplasty resulted in pain relief and improved range of motion. In 1995, Ryu and Fagan (3) reported on eight gamekeeper's thumbs with Stenor lesions treated arthroscopically. The proximally retracted ulnar collateral ligament was reduced into the joint with a nerve hook placed into the ulnar recess at the ligament origin. In this series, the ligament was simply reduced back into its anatomic location and left there without direct internal fixation. The joints were fixed with Kirschner wires. Postoperatively, all patients achieved good pinch strength, and seven of eight patients had no pathologic laxity of the MP joint. In 1998, Slade et al. (4) reported 10 patients with intra-articular fractures about the MP joints that were treated with arthroscopic assisted fracture reduction. These results compared favorably with standard open techniques with improved range of motion and shorter rehabilitation time. Each article cited focuses on a specific treatment given to a particular problem.

The overall utility of the technique of MP arthroscopy as a whole was not addressed, and there has been no comprehensive discussion of arthroscopy anatomy.

As more has been learned in general about the arthroscopic anatomy of major joints, new techniques have evolved to treat old orthopedic conditions. However, for the most part, open operative techniques for the treatment of intra-articular pathology about the MP joints are still being used. This article will explore the utility, indications, advantages, and technical aspects of MP joint arthroscopy through illustrative case histories. Arthroscopic anatomy will be dealt with systematically and in detail.

Address correspondence and reprint request to Dr. Leo M. Rozmaryn, The Orthopaedic Center, 9711 Medical Center Drive, Rockville, MD 20850, U.S.A.

■ INDICATIONS/ CONTRAINDICATIONS

In reviewing the literature and examining the current patient series, the following indications for arthroscopy have emerged:

- Synovectomy/biopsy
- Removal of foreign or loose body
- Capsular debridement and release
- Osteochondral lesions
- Juxta-articular lesions
- Intra-articular fractures
- Collateral ligament repair
- Locked MP joint

The advantages of arthroscopic versus open surgery of the MP joint with the appropriate indications are similar to those of larger joints. These include:

- Less surgical exposure—extensor hood is protected
- Excellent joint visualization
- Short learning curve
- Immediate postoperative joint mobilization
- Shorter rehabilitation period

However, to benefit from the technique, one must be completely familiar with the arthroscopic anatomy of the MP joint. As is true in larger joints, it is not intuitive and is completely different than the anatomy presented during dissection. Additionally, viewing the joint arthroscopically allows a unique perspective into the kinesthetics of the joint and the function of the ligament fiber bundles as primary restraint.

■ TECHNIQUES

Under a regional or local anesthetic, patients were placed in the supine position with the shoulder abducted and the elbow flexed to 90°. The affected digit was suspended with a finger trap from an overhead traction device with 5 pounds of tension (Fig. 1). The joint was insufflated with a 3 cc saline syringe and 25-gauge needle. Two dorsal portals were developed: radial and ulnar to the central extensor tendon in the digits and to the extensor pollicis longus (EPL) tendon and extensor pollicis brevis (EPB) in the thumb. A #11 blade is used to open the skin and sagittal shroud fibers. Care is taken not to injure the central extensor tendon slip in the palmar digits and the EPL in the thumb. A blunt conical probe was used to open the joint capsule, and the 2 mm, 0° small joint arthroscope is placed initially into the radial portal. Inflow with an intravenous saline bag and tubing and lighting are established. There is no outflow until the 2.5

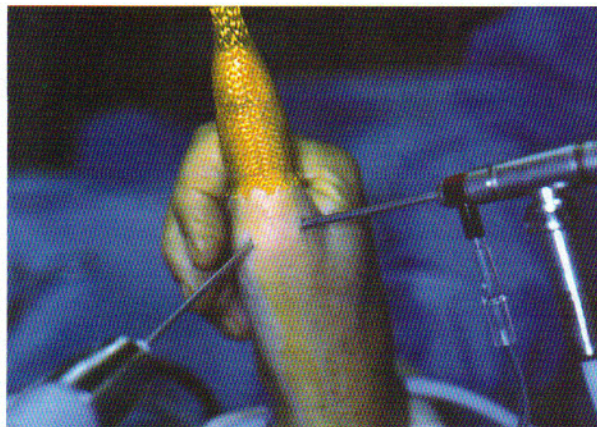


FIG. 1. Operating room set-up for metacarpophalangeal arthroscopy. Reprinted with permission from W.B. Saunders Company.

mm shaver is placed into the ulnar portal. The instrument and arthroscope portals are interchangeable. Standard small joint arthroscopic hand instruments fit easily into the MP joint. All standard small joint instrumentation such as nerve hooks, hand scissors, punches, 2 mm shavers, Acuflex blades (Acuflex Microsurgical, Inc., Mansfield, MA), and radiofrequency probes are easily used through this approach.

■ ARTHROSCOPIC ANATOMY

Examining the joint through the radial portal, the following anatomic landmarks are visualized: The metacarpal head and the articular surface of the proximal phalanx are examined from radial to ulnar, from the dorsal capsule to the volar plate. The metacarpal head is wider at the volar end than the dorsal. The surfaces are examined for integrity of the cartilage surfaces and for the presence or absence of degenerative changes. In most joints the articular surface of the proximal phalanx is ringed by a fibrocartilaginous “meniscus” (Fig. 2; labeled **M**) that appears to serve as a shock absorber for forces traveling across the MP joint. The figure depicts the view looking up at the articular surface of the proximal phalanx from the joint space. The structure labeled **M** represents the cartilaginous rim of the articular surface. The main collateral ligaments are easily visible across the joint. These are in reality a bundle of three vertically oriented fibers (Fig. 3) that originate in the ulnar recess (Fig. 4A) at the side of the metacarpal head and run to the base of the proximal phalanx. At the origin, the ligament fibers twist and coil (Fig. 4B), and with digital flexion these uncoil to accommodate the widened metacarpal head in flexion as well as the longer axis of rotation in flexion caused by the cam shape of the head in the sagittal plane. With flexion and extension, there is differential tensing of the fibers with equal tension in full extension and increased

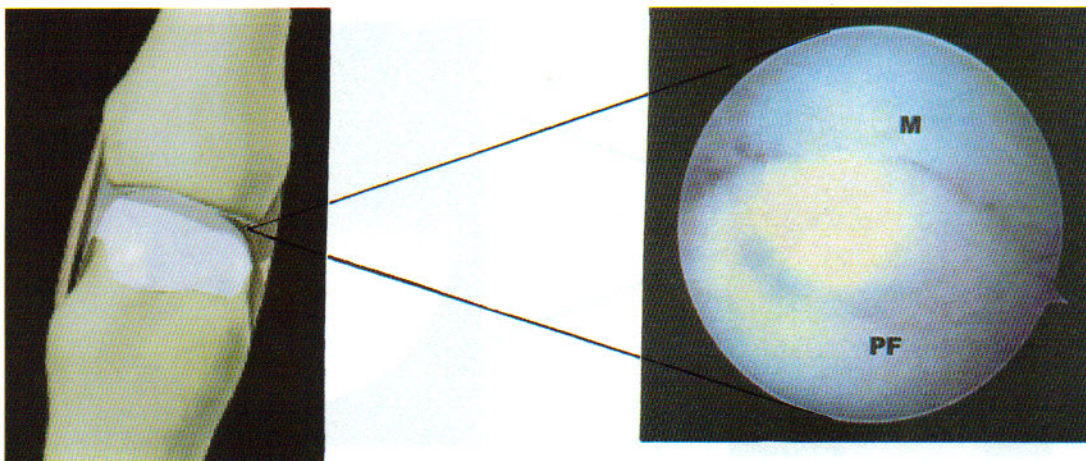


FIG. 2. “Circumferential meniscal” rim (M) of the articular surface of the proximal phalanx (PF). Reprinted with permission from W.B. Saunders Company.

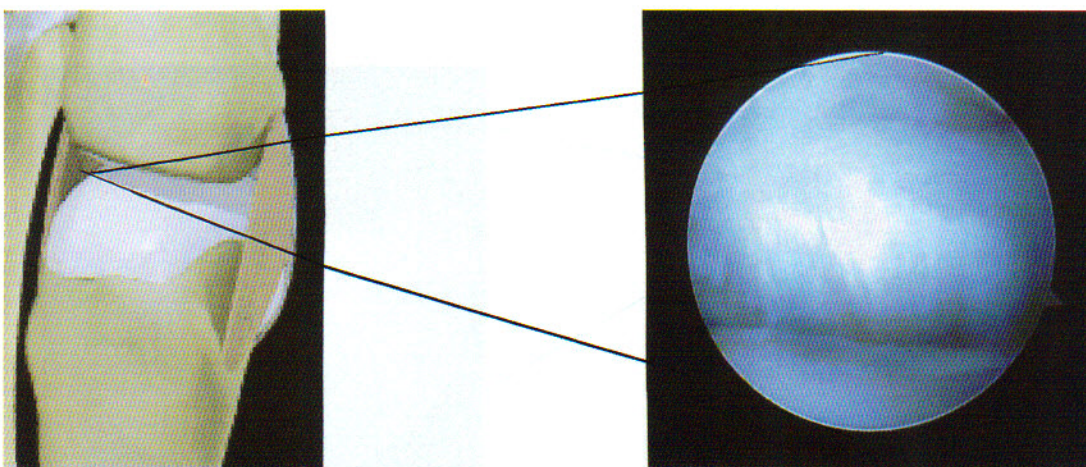


FIG. 3. Ulnar collateral ligament index MP joint notes the three distinct bundles. With joint motion, there is relative motion between the fiber bundles. Arthroscopic image reprinted with permission from W.B. Saunders Company. Anatomic image reprinted with permission from Primal Pictures, London, England.

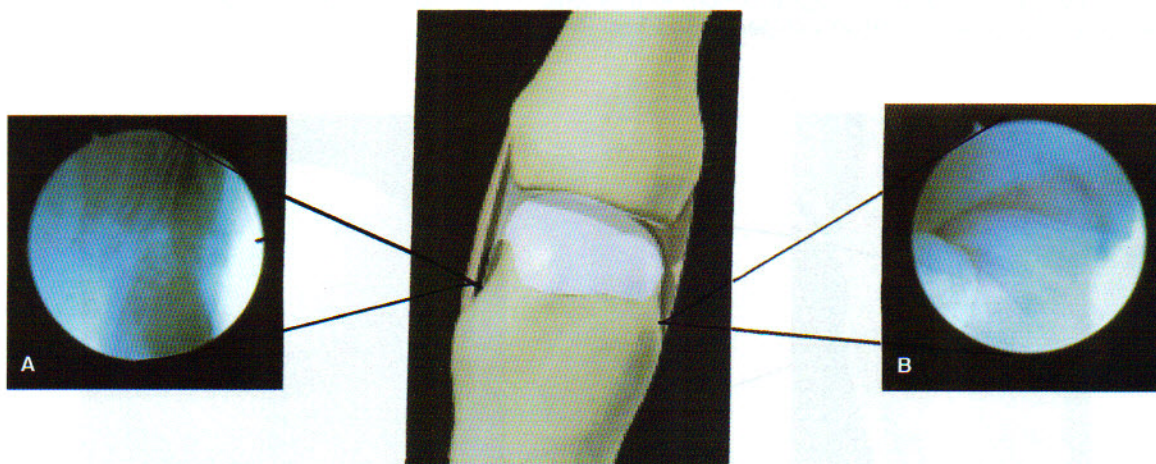


FIG. 4. **A.** The lateral recess between the side of the metacarpal head and the collateral ligament. Reprinted with permission from W.B. Saunders Company. **B.** The origin of the ulnar collateral ligament at the side of the metacarpal head. Note the spiral shape of the origin. With digital flexion the ligament origin uncoils to accommodate the greater distance to the center of rotation. Reprinted with permission from W.B. Saunders Company. Anatomic image reprinted with permission from Primal Pictures.

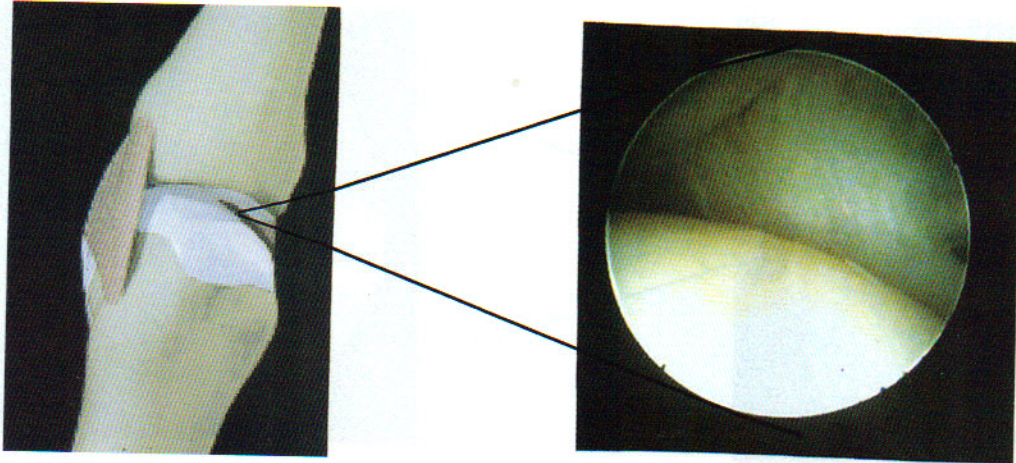


FIG. 5. The accessory collateral ligament stretching from the metacarpal head to the volar plate. The proximal phalanx is above and the volar plate is to the left. Reprinted with permission from Primal Pictures.

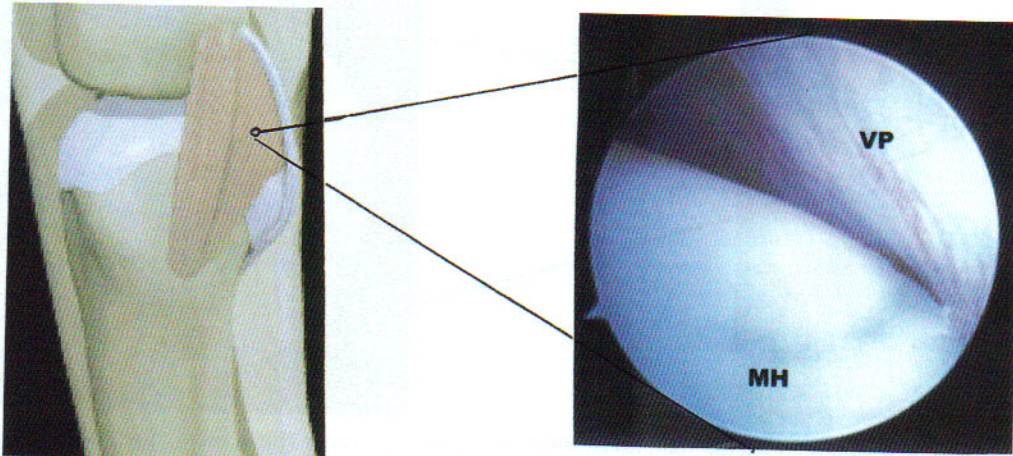


FIG. 6. The volar plate (VP) with the MP joint in extension. The close apposition to the metacarpal head (MH) and the tautness of the ligament relax with digital flexion. Arthroscopic image reprinted with permission from W.B. Saunders Company. Anatomic image reprinted with permission from Primal Pictures.

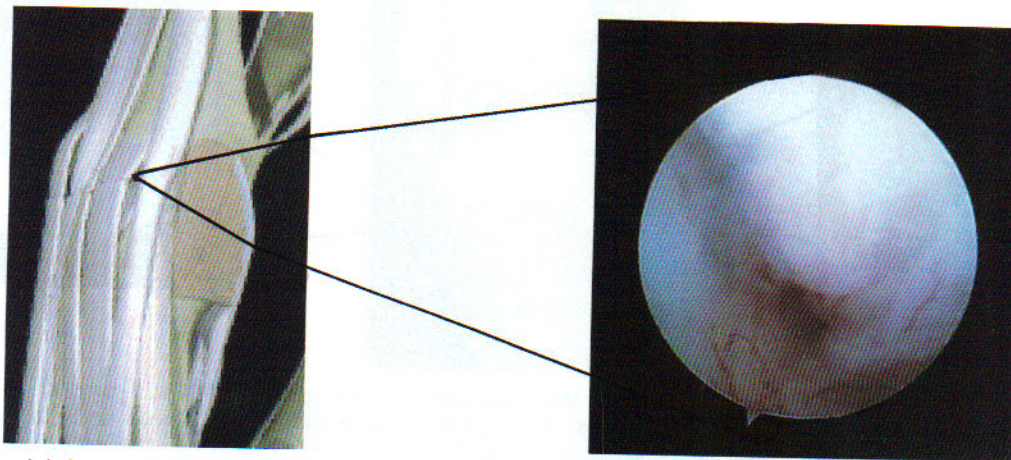


FIG. 7. Synovial tissue in the dorso-proximal recess underlying the extensor tendon. Reprinted with permission from Primal Pictures.

tension on the dorsal fibers as the digit moves into flexion. Volar and deep to the main collateral ligament lies an amorphous fibrous layer that leads to the volar plate. The fibers are less well defined and are thinner in consistency. This is the accessory collateral ligament (Fig. 5). The volar plate is a thickened vascular rich ligament that stretches obliquely from the metacarpal head to the proximal phalanx articular surface (Fig. 6). With flexion of the finger, the volar plate is seen to relax and become less oblique, and with extension it becomes taut and drapes around the metacarpal head. It is only during flexion that a recess becomes apparent between the metacarpal head and the volar plate. A small amount of synovium rests in this recess. During digital extension, this recess closes and becomes inaccessible.

The dorsal capsule begins at the well-defined dorsal boundary of the main collateral ligament. The fibers are thinner and ill defined, with fibers running longitudinally. The junctional fibers between the dorsal capsule and the main collateral ligament run obliquely in both directions, forming a weave. Distally the fibers attach directly to the meniscus surrounding the articular surface of the proximal phalanx. Proximally, the dorsal fibers extend into a recess around the metacarpal head. The recess is filled with areolar and synovial tissue (Fig. 7).

This recess is easily entered and explored when the digit is in full extension. On each side of the metacarpal head lies a narrow recess that is accessible only in the thumb and large digits. It is, as well, filled with areolar tissue and synovial folds. The origin of the main collateral ligaments is visible in these recesses.

The MP joint of the thumb is similar in most respects to the palmar digits, but there are a few notable exceptions. The volar plate is covered by a layer of synovium, which when removed shows the articular surface of two sesamoid bones embedded in the volar plate. These rise and fall with respect to the metacarpal head with thumb extension and flexion. These are occasionally apart from one another (Fig. 8A) or they may lie together (Fig. 8B). There is a notable absence of a meniscus surrounding the articular surface of the proximal phalanx. The arrangement of the collateral ligaments is similar to the palmar digits, but the radial and ulnar recesses are deeper, wider, and easily accessible.

■ CASE HISTORIES

The following cases illustrate the utility of this technique in treating a variety of other conditions.

Case 1

A 55-year-old man was struck 3 months earlier by a baseball on the left index finger and had pain on the radial aspect of the MP joint. X-rays were negative. Pain

increased markedly with active and passive motion of the MP joint. He was treated for 2 months with splinting, steroid injections, hand therapy, and antiinflammatory medications but obtained no relief. Certain motions created locking, crepitance, and intense pain in the joint. Magnetic resonance imaging (MRI) showed a subchondral cyst. Arthroscopy indicated synovitis and numerous full-thickness cartilaginous erosions and loose bodies (Fig. 9A and 9B). The loose bodies were removed, the bone surfaces abraded, and a synovectomy was done. At 9 days postoperatively, his preoperative locking was gone and crepitation was diminished, but pain persisted at 70° flexion. At 3 months, he had 75° of flexion with lessened pain. Diagnosis: Post-traumatic arthritis.

Case 2

A 41-year-old attorney had a history of gout that was controlled by allopurinol and indomethacin. For 2 months, he had pain, redness, and swelling in the right index MP joint that had not responded to antibiotics and splinting. There had been no previous infection, puncture wound, or arthritis. He had a negative rheumatoid screen and denies any trauma. His MP joint was grossly swollen and dark red. His range of motion was -15° of extension and 45° of flexion actively and passively. Arthroscopy showed no evidence of synovitis. There were no articular cartilage defects or erosions. The collateral ligaments were frayed and stretched as if traumatized, and there were small osteochondral fragments floating in the joint (Fig. 10). The ligament edges were debrided, the fragments removed, and a bulky dressing applied. At 10 days, the dressing was removed, and the MP joint appeared free of any swelling or ecchymosis, but the exposed proximal interphalangeal (PIP) joint appeared bruised and swollen. When I indicated to the patient that he "must have traumatized the finger somehow," the patient became belligerent and defensive. I placed the patient into a short arm cast with the fingers covered. The following day he returned and demanded that the cast be removed. The patient's wife contacted me separately and indicated that her husband was behaving "strangely" at home. A psychiatric referral was recommended. Diagnosis: factitious disorder.

Case 3

A 38-year-old man, active in sports, had multiple basketball injuries to his right index finger. For several months, he had crepitus, swelling, clicking, sudden transient locking, and pain aggravated by use and flexion beyond 60°. There was no response to 6 weeks of splinting, steroid injection, and hand therapy. MRI suggested an osteochondral defect in the head of the metacarpal. Arthroscopy showed diffuse chondromalacia of the metacarpal head, synovitis, and a large sagittal tear of the

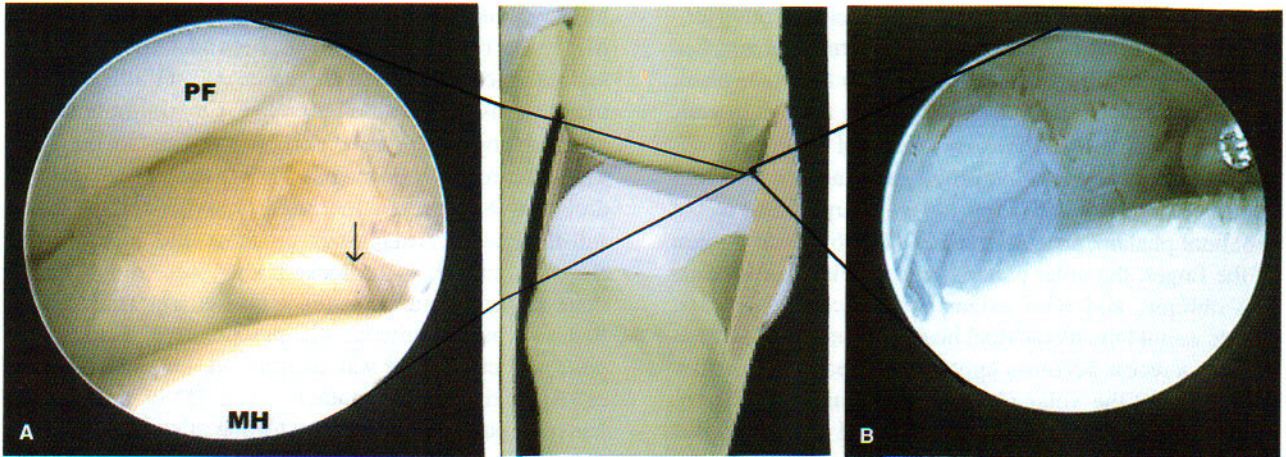


FIG. 8. **A.** One of two sesamoid bones embedded in the volar plate (arrow). **B.** In some specimens, the sesamoids were apart, and in some, they were adjacent to one another. Note the proximity to the proximal phalanx (PF) and the metacarpal head (MH). Reprinted with permission from W.B. Saunders Company.

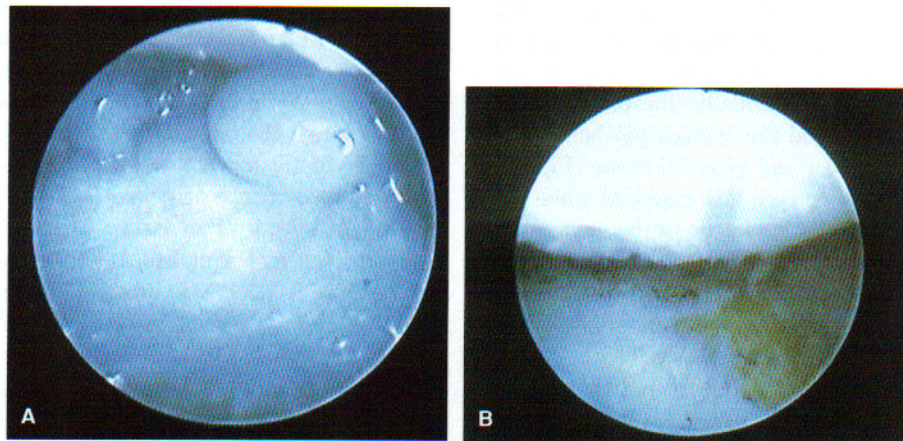


FIG. 9. **A.** Osteocartilaginous loose body in the MP joint. **B.** Full-thickness erosion of the articular surface of the proximal phalanx.

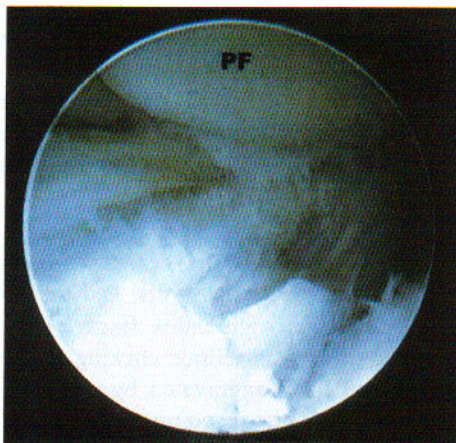


FIG. 10. Collateral ligaments fraying near its insertion into the proximal phalanx (PF) and joint debris in this patient, who emphatically denied trauma. Only minimal synovitis is seen.

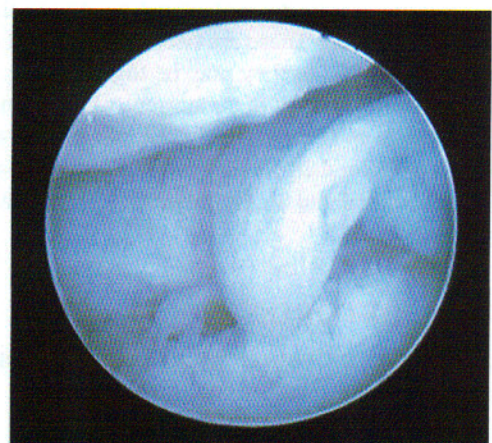


FIG. 11. Sagittal tear of the volar plate with the distal end enfolded into the joint.

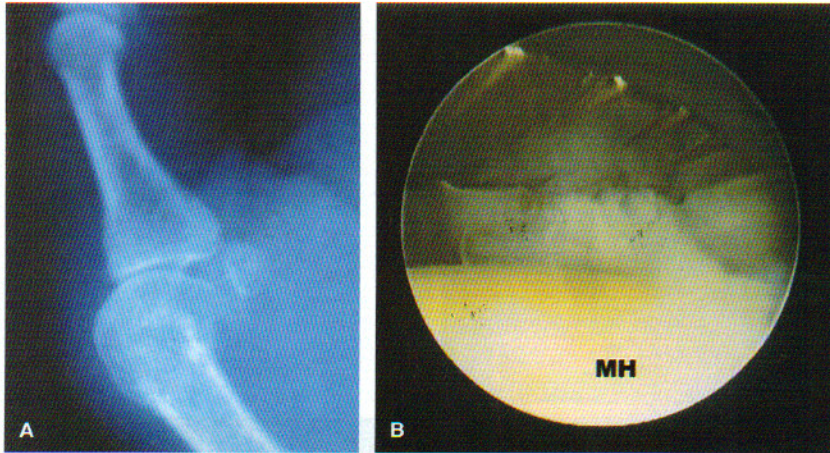


FIG. 12. A. Lateral x-ray of the thumb, showing chronic volar subluxation of the MP joint of the thumb. Note the early degenerative changes. B. The volar plate being released with an Acuflex blade. It is critical that the release be done layer by layer with broad sweeping strokes to avoid deep puncture and possible digital nerve injury. Care must also be taken not to scuff the metacarpal head (MH).

volar plate detached distally and enfolded into the joint (Fig. 11). All of these were debrided, and postoperatively the pain abated, the crepitation subsided, and the locking disappeared. At 10 days, the patient's range of motion had returned to normal, and the patient returned to his regular activity without further complaint. Diagnosis: Locked MP joint.

Case 4

A 39-year-old trucker had sustained a volar MP dislocation of his thumb 1 month earlier. The patient had arrived for primary treatment at 1 month because of deformity, persistent swelling, and pain. X-rays showed volar subluxation of the proximal phalanx on the metacarpal head (Fig. 12A). There was a 45° flexion contracture of the MP joint and approximately 30° painful passive motion. Arthroscopy showed synovitis and the presence of fibrous bands around the periphery of the joint. The volar plate was markedly fibrotic and thickened. An Acuflex blade was used to release the volar plate (Fig. 12B) and the volar aspect of both collateral ligaments. After a complete synovectomy and debridement, the joint was reduced and secured with a K-wire. At 1 month, the wire and cast were removed and hand therapy commenced. At 2 months postoperatively, he was able to extend the joint to neutral and flex to 60° without pain. A home-strengthening program was started. Diagnosis: Chronic subluxation of the MP joint.

Case 5

A 45-year-old woman had a 6-month history of localized pain on the volar radial aspect of the right thumb at the MP joint after a fall. There was no pain or crepitation with movement, but there was marked localized tenderness over the radial sesamoid. X-rays were negative. Three months of hand therapy, antiinflammatory medications, and splinting produced no effect. Arthroscopic

evaluation indicated localized chondromalacia and synovitis at the articular surface of the sesamoid (Fig. 13). The sesamoid was deemed too large to remove arthroscopically, so it was removed with open technique. Preoperative pain promptly disappeared and remained so at 6 months' follow-up. Diagnosis: Sesamoiditis.

Case 6

A 47-year-old man fell off a horse and sustained a hyperabduction injury to the thumb. X-ray showed an intra-articular fracture of the volar base of the proximal phalanx (Fig. 14A). There was abduction laxity to the MP joint. Arthroscopic evaluation indicated a displaced articular fracture with the fragment connected to an attenuated ulnar collateral ligament. The fragment was reduced with a nerve hook and pinned under direct visualization (Fig. 14B, C, and D). The MP joint was pinned as well and immobilized for 4 weeks. The fracture pins were removed at 6 weeks, and strengthening exercises were begun. At 8 weeks, there is a good stability to abduction

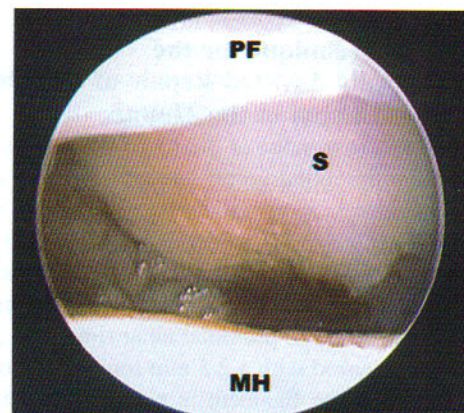


FIG. 13. Sesamoiditis. Note the chondromalacia of the articular surface of the sesamoid (S) and the localized synovitis at the inferior margin of the sesamoid.

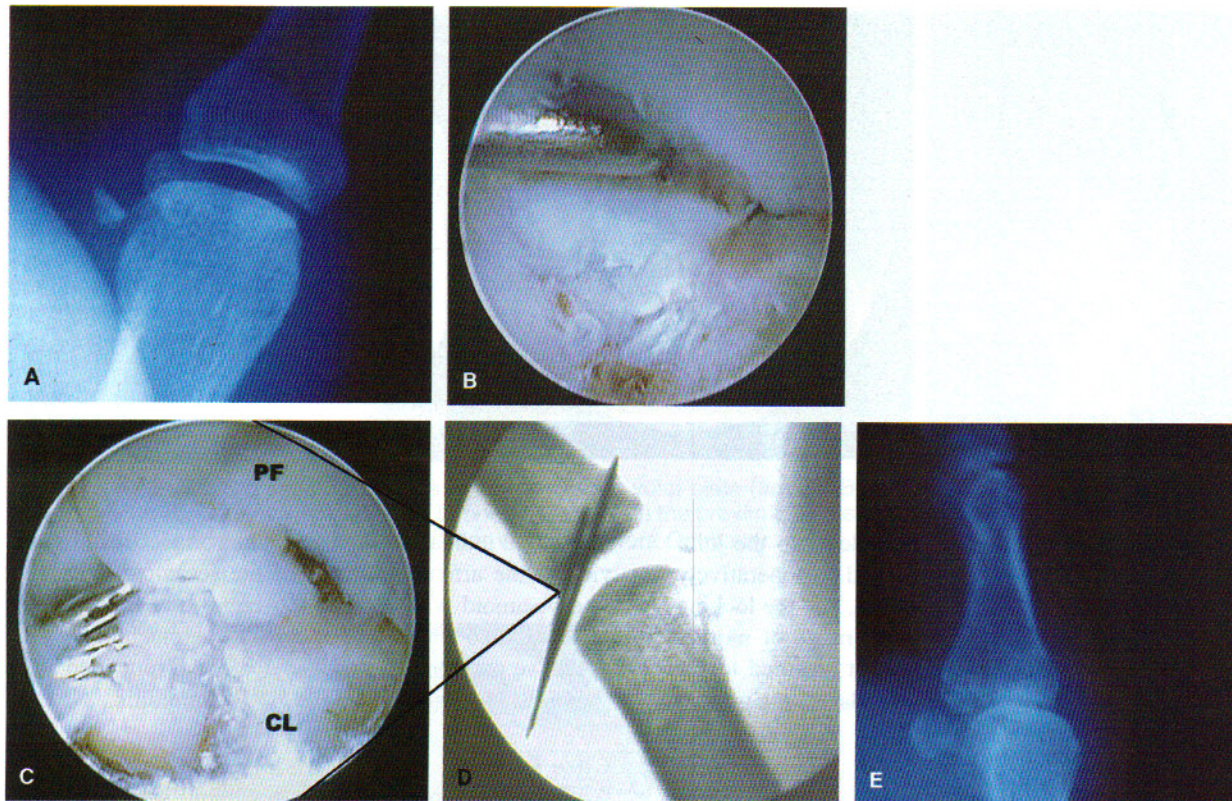


FIG. 14. **A.** AP x-ray of the thumb, showing a displaced articular fracture of the proximal phalanx at the insertion of the ulnar collateral ligament. This represents a ligamentous avulsion. **B.** Arthroscopically assisted pinning of the intra-articular fragment of the proximal phalanx (PF) after reduction with a nerve hook. Note the fraying of the collateral ligament (CL) under the osteochondral fragment. **C.** The osteochondral fragment with the K-wires in place. The wires are placed manually through the skin, compressing the fragment in. Once reduction is achieved, the wires are drilled through the phalanx. **D.** Postoperative x-ray of the fracture reduced and pinned with crossed K-wires. **E.** At 2 months, the fracture is healed anatomically, and stability of the thumb has been restored.

stress, and the pain is subsiding. At 2 months, x-rays showed good apposition of the bone fragment and healing (Fig. 14E). Diagnosis: Ulnar collateral ligament injury with intra-articular fracture

A Suggested Technique for the Arthroscopically Assisted Repair of the Ulnar Collateral Ligament of the Thumb

With the thumb suspended in 2.3 kg of traction with the arthroscope in the radial portal, the undersurface of adductor aponeurosis is visualized covered with wispy hemorrhagic remnants of the collateral ligament (Fig. 15A). A nerve hook placed into the ulnar recess will deliver the ulnar collateral ligament (Stener lesion) into the joint (Fig. 15B). The proximal ulnar rim of the proximal phalanx is burred with a 2.5 mm round bur, creating a "raw" surface. The ligament is pierced and threaded (by hand) by two percutaneously placed meniscal repair needles that have threading loops at the other end (Fig. 15C and E). The wires are driven across the base of the

proximal phalanx, thus approximating the ligament to the "raw edge" of bone (Fig. 15D). A small skin incision measuring 4 mm is made, connecting the needles down to the adductor aponeurosis. A single 3 to 0 prolene suture is threaded through both needle loops, and these are pulled through the other side (Fig. 15F). As the suture is pulled, the ligament is pulled up toward the bone (Fig. 15G). The sutures are tied over a button. The thumb is immobilized in a splint for 10 days, and a cast is applied for 4 weeks. The button is removed, and exercises are begun.

This technique is still experimental, and further follow-up and study are necessary to document its effectiveness.

CONCLUSION

Only six papers have been written on the subject since 1979. I believe this is attributable to a perception that the MP joint is simply too small to perform operative arthroscopy in a meaningful and practical fashion. It is not

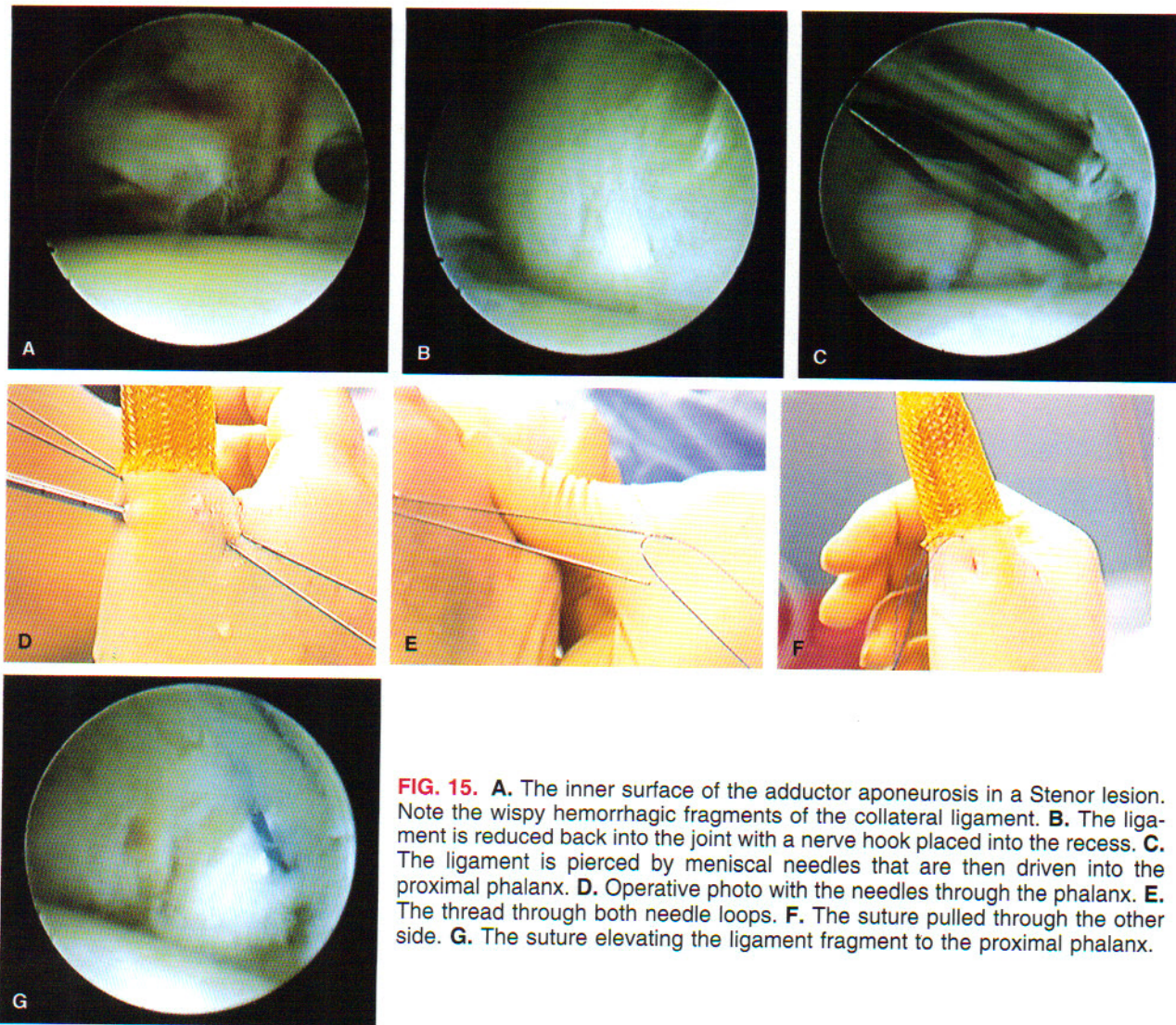


FIG. 15. **A.** The inner surface of the adductor aponeurosis in a Stenor lesion. Note the wispy hemorrhagic fragments of the collateral ligament. **B.** The ligament is reduced back into the joint with a nerve hook placed into the recess. **C.** The ligament is pierced by meniscal needles that are then driven into the proximal phalanx. **D.** Operative photo with the needles through the phalanx. **E.** The thread through both needle loops. **F.** The suture pulled through the other side. **G.** The suture elevating the ligament fragment to the proximal phalanx.

the purpose of this article to describe long-term outcomes of this, but rather to acquaint the reader with the utility of these techniques. The experience of the authors is consistent with those who have reported previously that this technique is highly utilitarian and effective when used for the appropriate indications. Future work on the arthroscopic anatomy of the MP joint should further delineate the kinesthesiology of this joint and the function of individual fiber bundles in the capsule that surrounds the MP joint.

■ REFERENCES

- 1) Chen YC. Arthroscopy of the wrist and finger joints. *Orthop Clin North Am* 1979;10:723-33.
- 2) Declercq G, Schmitgen G, Verstreken J. Arthroscopic treatment of metacarpophalangeal arthropathy in hemochromatosis. *J Hand Surg (Am)* 1995;19:212-4.
- 3) Ryu J, Fagan R. Arthroscopic treatment of acute complete metacarpophalangeal ulnar collateral ligament tears. *J Hand Surg (Am)* 1995;20:1037-42.
- 4) Slade JF 3rd, Gutow AP. Arthroscopy of the metacarpophalangeal joint. *Hand Clin* 1999;15(3):501-27. Review.
- 5) Vaupel GL, Andrews JR. Diagnostic and operative arthroscopy of the thumb metacarpophalangeal joint: a case report. *Am J Sports Med* 1985;12:139-41.
- 6) Wilkes LL. Arthroscopic synovectomy in the rheumatoid metacarpophalangeal joint. *J Med Assoc GA* 1987;76: 638-9.