

31

Hand Osteoarthritis*Leo M. Rozmaryn, MD***Synonyms**

Arthritis
 Degenerative arthritis
 Osteoarthritis
 Degenerative joint disease
 Joint destruction

ICD-9 Codes

715.14
 Osteoarthritis, primary,
 localized to the hand
 715.24
 Osteoarthritis, secondary,
 localized to the hand
 716.14
 Traumatic arthropathy of
 the hand

Definition

Osteoarthritis of the hand is a degenerative condition in which the hyaline cartilage disorder develops in the diarthrodial joints of the hand. It is distinct from inflammatory arthropathies such as rheumatoid arthritis in which the primary component is an inflammatory or systemic pathophysiology. Primary idiopathic osteoarthritis is reserved to describe situations in which articular cartilage degeneration occurs without clear etiology. Idiopathic osteoarthritis excludes post-traumatic arthritis or arthritic conditions resulting from pyrophosphate deposition disease, infection, or other known causes. The prevalence of osteoarthritis of the hand increases with age and is more common in men than women until menopause. In individuals older than 65 years, osteoarthritis of the hand has been estimated to be as high as 78% in men and 99% in women.¹ The distal interphalangeal and proximal interphalangeal joints and the base of the thumb are the most affected joints.

Symptoms

Patients typically report pain, stiffness, episodic swelling, erythema, and induration of the affected joints. Initially, the pain and the stiffness may be mild, but over time, symptoms progress steadily. Pain is commonly worse at night and may affect one or more digits or one or more joints in the same digit. Stiffness and pain are also common first thing in the morning. A certain percentage of patients feel no pain but experience a steadily progressive enlargement of the affected joints with stiffness and a loss of function. It is not understood at this time why some patients have pain and some do not.

Physical Examination***Distal Interphalangeal Joint***

Osteoarthritis of the distal interphalangeal joint is characterized by primary enlargement of the distal joint with formation of so-called Heberden's nodes (Fig. 1). It is often painless and unnoticeable, primarily because of the deformity near the joint. After loss of joint space and formation of Heberden's nodes, angulatory and rotatory deformities of the terminal phalanx can develop (Fig. 2). Modular involvement of the joint

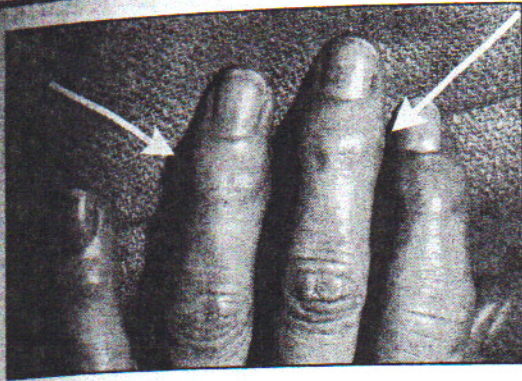


FIGURE 1. Patients with degenerative joint disease of the hands can present with Heberden's nodes (arrows). These nodules represent osteophytes at the DIP joint. (From Concannon MJ: *Common Hand Problems in Primary Care*. Philadelphia, Hanley & Belfus, 1999, with permission.)

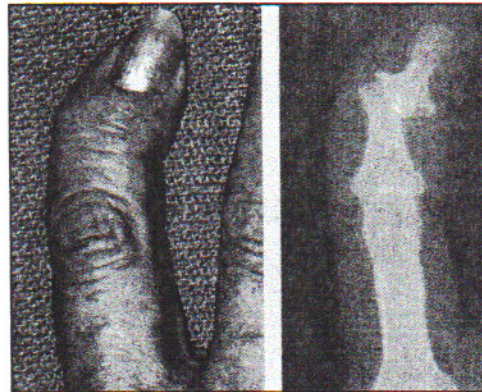


FIGURE 2. Severe osteoarthritis at the DIP joint of the fifth finger. Osteophyte formation, joint destruction, and angulation are demonstrated. (From Concannon MJ: *Common Hand Problems in Primary Care*. Philadelphia, Hanley & Belfus, 1999, with permission.)

combined with bone spurs can lead to the formation of ganglion cysts or mucous cysts on the dorsal aspect of the distal interphalangeal joint. There may be secondary deformity of the nail plate, with grooving and splitting of the nail plate. The proximal interphalangeal joint is less commonly involved with osteoarthritis than the distal joint. Again, the development of progressive pain, stiffness, and enlargement of the joint with periodic flares of erythema and increased pain may occur. The development of a progressive flexion deformity and contracture of the joint or an angulatory or rotatory deformity such as ulnar deviation of the finger as the joint space collapses are also possible. Some patients may have severe deformities of the proximal interphalangeal joints with no pain.

Metacarpophalangeal Joint

Osteoarthritis in the metacarpophalangeal joint usually results in pain, swelling, grinding, and loss of movement of the joint. Digital deformity in the radial ulnar plane is rare, although flexion deformities are common. These may involve one or several metacarpophalangeal joints at the same time.

Trapeziometacarpal Joint

The trapeziometacarpal joint is a very common site for the development of osteoarthritis. This complex saddle joint that allows thumb flexion, extension, abduction, adduction, and circumduction may fail as the articular cartilage degenerates and there is loosening of the complex primary ligamentous and secondary muscular restraints around the carpometacarpal joint. This condition may be accompanied by joint subluxation at the metacarpal base.² Onset of pain may be vague and can take months or even years to become clinically evident. Osteoarthritis presents with pain and crepitation and the characteristic deformity on the radial aspect of the base of the metacarpophalangeal joint. Any compressive or rotatory movement becomes very painful. Curiously, there is poor correlation between the radiographic appearance of the joint and the degree of symptoms. Patients gradually become unable to perform even the simplest tasks of daily living.

Examination of any of these joints will include documenting the active and passive range of motion of these joints. The presence of peri-articular bone spurs or osteophytes should be noted. The condition of the skin, whether it is erythematous and the pain exhibited by the patient when

passive movement to the joint is attempted should be noted. The arc of active and passive movement should be documented as well. Grip and pinch strength are usually diminished. The digits and the thumb need to be evaluated for dynamic or static deformities, and the degree of deformity should be noted. Neurologic examination including sensation and deep tendon reflexes should be normal.

Functional Limitations

Functional limitations include weak grasp, pain, and stiffness with finger movement, impeding manual exertion. This may limit opening jars and doors, or gripping a steering wheel or tools. Fine motor tasks become increasingly difficult as the pain, stiffness, and deformity progress. Patients may have difficulty typing at work, opening mail, chopping vegetables, buttoning clothes, tying shoelaces, etc.

Diagnostic Studies

The imaging modality of choice is the plain x-ray. Characteristic findings include joint space narrowing, subchondral sclerosis, osteophyte formation, and degenerative cyst formation in the subchondral bone. As the joint space collapses, there may be shortening of the involved digit or ulna deviation of the digits. Four radiographic changes are characteristic of basal joint arthritis of the thumb.³ In stage I the articular contours are normal with no subluxation or joint debris. The joint space may be widened if an effusion is present. In stage II there is slight narrowing of the thumb trapezial metacarpal joint, but the joint space and articular contours are preserved. Joint debris is less than 2 mm and may be present. In stage III there is significant trapezial metacarpal joint destruction with sclerotic resistive changes and subchondral bone with osteophytes greater than 2 mm. Stage IV is characterized by pantrapezial arthritis in which both the trapezial metacarpal and scaphoid trapezial joints are affected. The base of the thumb metacarpal may be radially subluxed early in the disease.

Differential Diagnosis

Inflammatory arthritis (e.g., lyme disease, gout, rheumatoid arthritis, psoriatic arthritis)

Calcium pyrophosphate deposition disease

Septic arthritis

Systemic lupus erythematosus

Scleroderma

Treatment

Initial

Initial treatment of osteoarthritis of the hand and wrist is directed from mechanical and biologic aspects of the disease. To decrease mechanical stresses in the affected joints, activity modification, rest, and judicious splinting are appropriate. For the interphalangeal joint, finger splints for night use and selective day use can be considered. For the basilar thumb joint, an opponens splint, either hand-based or across the wrist, can be beneficial. Similarly, a cock-up brace can be used for intercarpal and radial carpal osteoarthritis. The medical treatment of osteoarthritis includes NSAIDs/COX-2 inhibitors. Although there is a myriad of these medications available, no single compound has been found to be singularly effective in the treatment of osteoarthritis. Recently the use of chondroitin sulfate,³ glucosamine,⁴ and the intra-articular injection of Hyalgan⁵ have been advocated. Capsaicin cream can also be tried.

Rehabilitation

Therapeutic intervention for conservative, non-operative treatment of osteoarthritis begins with resting the involved joints. Activities that stress the joint should be identified and modified or discontinued. Instruction in joint protection (Table 1) and work simplification techniques is helpful, as well as encouraging the patient to perform routine tasks more proficiently and with less stress to the joints.

For the arthritic patient, hand splints are used to rest inflamed joints, maintain proper joint alignment, improve functional control, and support weak structures. The most commonly used splints include a resting hand splint, ulnar deviation splint, tri-point proximal interphalangeal joint splint, and thumb spica splint. Each splint should be fabricated to minimize interference with the uninvolved joint function and maximize independence and activities of daily living. Patients should be supplied with instructions on the splint wear time, care procedures, donning and doffing procedures and skin care. Therapeutic modalities such as warm water soaks and paraffin baths are used in the treatment of the non-acute arthritic hand. Contraindications for using heat on an arthritic hand include acute exacerbation of joint inflammation, peripheral neuropathies, auto sensory disturbances, and skin irritations or open wounds. Gentle range-of-motion exercise of all digits is helpful, preceded by application of moist heat.

Procedures

Injections can be used for painful arthritic joints. These are typically done no more than 2 to 3 times annually using a corticosteroid/anesthetic preparation (Fig. 3).

Under sterile conditions, using a 25- to 27-gauge needle and a mixture of local anesthetic (e.g., 0.5 to 1 cc 1% lidocaine) and corticosteroid (e.g., 0.5 to 1 cc triamcinolone), the joint is injected. It is

TABLE 1 Basic Principles of Joint Protection

1. **Respect pain:** The patient must learn to distinguish between a debilitating pain that can exacerbate symptoms versus an uncomfortable pain associated with a particular activity. Activities ought to be modified on that basis.
2. **Balance activity and rest:** The patient's daily activity schedule must be outlined and modified to ensure proper planning, pacing, and prioritization of activities. Daily routines must incorporate adequate time for rest that involves joints.
3. **Employ work simplification techniques:** Patients are encouraged to use proper body mechanics and to arrange their living quarters and daily routines to minimize unnecessary use of energy and unnecessary stress on the joints.
4. **Maintain strength and range of motion:** Patients are encouraged to maintain at least minimal involvement in the majority of self-care tasks to preserve active range of motion. Daily activities may be supplemented with active range-of-motion exercises targeted for specific joints.
5. **Avoid positions of deformity:** Positions or motions that stress the joint toward positions of deformity are to be avoided or eliminated. Ulnar stress and twisting motions are to be avoided.
6. **Use stronger muscles and larger joints:** The patient is taught adaptive techniques in which less stress is placed on the smaller joints and weaker muscles of the hand. In addition, the patient should be taught to carry items close to the body or cradle them in the entire arm to distribute loads, rather than relying on smaller muscles and joints of the hand to bear the entire load.
7. **Use adaptive equipment or splints:** The patient is provided with information on specific adaptive devices that are helpful in reducing or eliminating positions of deformity or unnecessary stress on the smaller joints. Splints are fabricated as indicated to preserve joint integrity and to avoid positions of deformity.
8. **Avoid activities that cannot be interrupted or stopped:** Strenuous activities that may cause severe pain or joint stress should be avoided. Activities such as lifting a small child or carrying a hot pan should be discouraged because the patient is not only at risk for joint stress, but also for injury to others and further injury to himself or herself if the hand cannot withstand the joint forces.
9. **Avoid sustained positions:** Sustained gripping should be eliminated. The patient is encouraged to use frequent rests or adaptive equipment to avoid static positions that facilitate joint stress and muscle fatigue.⁶

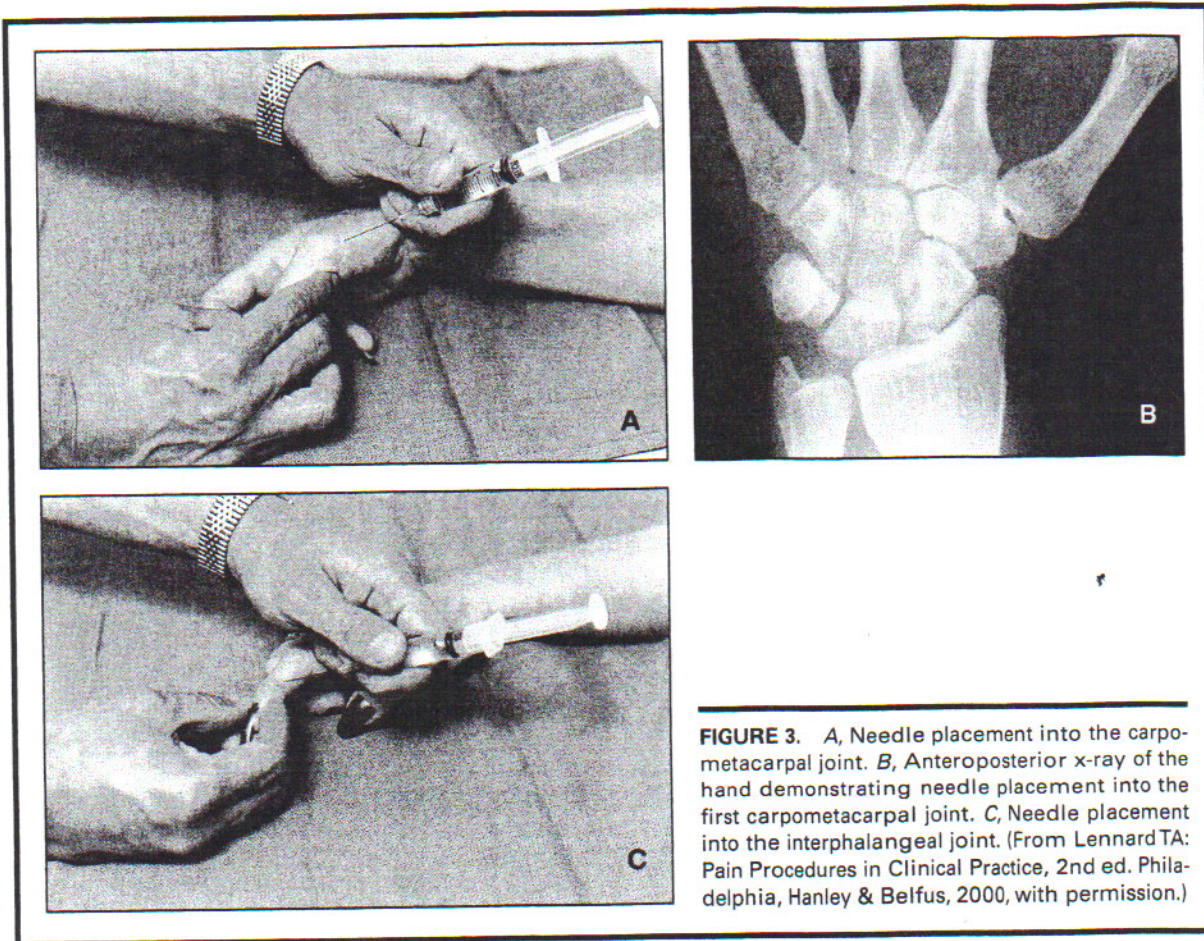


FIGURE 3. A, Needle placement into the carpo-metacarpal joint. B, Anteroposterior x-ray of the hand demonstrating needle placement into the first carpo-metacarpal joint. C, Needle placement into the interphalangeal joint. (From Lennard TA: Pain Procedures in Clinical Practice, 2nd ed. Philadelphia, Hanley & Belfus, 2000, with permission.)

important to note that small joints of the hand will not accommodate large volumes, so the total amount of fluid injected should typically be in the range of 1 to 2 cc.

Post injection care may include icing for 5 to 10 minutes and splinting the injected joint for up to 1 week after the procedure.

Surgery

Distal Interphalangeal Joint

For the mucous cyst and painful Heberden's nodes, the main surgical treatment has consisted of debridement of the Heberden's nodes and removal of the mucous cyst. In rare circumstances, when joint destruction is severe and maintenance of a distal interphalangeal joint is acceptable and alignment is difficult to achieve by other means, arthrodesis is considered, especially to correct severe angulatory or rotatory deformities that are functionally or cosmetically unacceptable to the patient.

Silicone interpositional arthroplasties have been described at the distal interphalangeal joint but have limited applications in this setting.

Proximal Interphalangeal Joint

The main indications for surgery are pain refractory to medical treatment, deformity that interferes with function, and contractures secondary to osteophyte formation and soft tissue fibrosis. Because proximal interphalangeal joint motion is so critical to normal hand functions, surgery should be avoided when an acceptable arc of motion is present. Infrequently, significant

instability associated with joint destruction, joint deformity, and pain is an indication for surgical reconstruction by arthrodesis or arthroplasty .

Total collateral ligamentous incision for fibrosis of the soft tissues in a contracted proximal interphalangeal joint has been demonstrated to be effective in relieving the contracture. This can be coupled with flexor tendon sheath release, volar plate contracture release, and modest, marginal osteophyte excision.

Arthrodesis is favored over arthroplasty in cases of gross instability, prior history of sepsis, deficient bone stock, and inadequate soft tissue coverage. There are multiple techniques for achieving arthrodesis.

Silicone implant arthroplasty remains a viable and appropriate treatment option for severe osteoarthritis of the proximal interphalangeal joints, and retrospective reviews of patients with proximal interphalangeal joint arthroplasties revealed excellent clinical results.⁷

Trapeziometacarpal Joint

The trapeziometacarpal joint is the most common upper extremity site of surgical reconstruction for osteoarthritis. The indications for surgery are primarily pain and secondary deformity⁶ that interferes with activities of daily living. The decision to treat basal joint disease and ultimately to perform surgery should be independent of x-ray staging. Patients may have severe disease on x-ray but not exhibit any pain. Ligamentous reconstruction using the slip of flexor carpi radialis tendon may be very effective in preventing further degeneration in early disease if joint surfaces are free of degeneration or chondromalacia but exhibit instability in subluxation.⁸

In more advanced disease, reconstructive efforts are directed at eliminating the painful arthritic joints about the trapezium to decrease pain and preserve function. Occasionally, trapeziometacarpal joint arthrodesis has been used, especially in young laborers; however, this results in the scaphoid trapezium joint bearing the brunt of all thumb motion after surgery and can result in arthrosis of that articulation.⁹

A more popular method of basal joint reconstruction is arthroplasty. This may vary from simple excisional arthroplasty in which the trapezium is removed, the metacarpal is held out to length using wires or external fixation, or a tendon is placed into positional material such as an "anchovy spacer" using a tendon graft. Other materials such as fascia, gel foam, and silicone have been used to treat and to fill the space left by the excision of the trapezium.¹⁰ Silicone implant usage has now fallen into disfavor because of the high incidence of resultant silicone synovitis and progressive joint destruction. Metal and plastic prostheses have been used with some success but have been found to loosen over time, necessitating further surgery. Spherical implants have recently been advocated, but it is too soon to evaluate their long-term effectiveness.¹¹ Most recently the Burton ligament reconstruction tendon interposition (LRTI) has been used as a modification of the original anchovy procedure. Long-term results have demonstrated that these ligament reconstructions have excellent long-term durability with pain relief and even late increases in strength.¹² There are some newer techniques for arthroscopic partial resection of the trapezium and interpositional arthroplasty, but again, it is too soon to assess their long-term effectiveness.

Potential Disease Complications

If left untreated this disease produces steadily increasing deformity, pain, and stiffness in the digits and the thumb with diminished strength, range of motion, and ability to carry on activities of daily living.

Potential Treatment Complications

Analgesics, NSAIDs, and COX-2 inhibitors have well-known side effects that most commonly affect the gastric, hepatic, and renal systems. The primary risks associated with injections include infection and an allergic reaction to the medication used. Potential surgical complications include wound infection, silicone implant synovitis, dissolution or extrusion of tendon interpositional spacers with proximal migration and impingement of the base of the thumb metacarpal, and loosening of trapeziometacarpal implantation with breakage of the implant.

Complications of arthrodeses procedures include non-union, infection, implant breakage, or extrusion. For digital silicone implants, breakage of the implants and synovitis have been reported.¹⁴

References

1. Chaisson CE, Zhang Y, McAlindon TE, et. al: Radiographic hand osteoarthritis incidents, patterns, and influence of pre-existing disease in a population base sample. *J Rheumatol* 1997;24:1337-1343.
2. Burton RI: Basal joint arthrosis of the thumb. *Orthop Clin North Am* 1973;4(2):331-348.
3. Eaton RG, Littler JW: A study of the basal joint of the thumb. Treatment of its disabilities by fusion. *J Bone Joint Surg* 1969;51A:661-668.
4. Ronca F, Palmieri L, Panicucci T, Ronca G: Anti-inflammatory activity of chondroitin sulfate. *Osteoarthritis Cartilage* 1998;6(Suppl A):14-21.
5. Towheed TE, Anastassiades TP: Glucosamine therapy for osteoarthritis. *J Rheumatol* 1999;26:2294-2297.
6. Corrado EM, Peluso GF, Gigliotti S, et. al: The effects of intra articular administration of highly uronic acid on osteoarthritis of the knee: A clinical study with the immunologic and biochemical evaluations. *Eur J Rheumatol Inflamm* 1995;15(1).
7. Dovel S, Heeter PK: *Hand Injuries: A Rehabilitation Perspective in Orthopedic Assessment and Treatment of the Geriatric Patient*. St Louis, Mosby, 1993, p 205.
8. Lynn HH, Wyrick JD, Stern PJ: Proximal interphalangeal joint silicone replacement arthroplasty: Clinical results using an interior approach. *J Hand Surg* 1995;20A:123-132.
9. Burton RI, Pellegrini VD Jr: Surgical management of basal joint arthritis of the thumb. Part 2: Ligament reconstruction with tendon interposition arthroplasty. *J Hand Surg* 1986;11A:324-332.
10. Eaton RG, Littler JW: A study of the basal joint of the thumb. *J of Bone and Joint Surg* 1969;51A:661-668.
11. Thompson JS: Complications and salvage of trapezial metacarpal arthroplasties. In Barr JS Jr (ed): *Instructional course lectures XXXVIII*. Park Ridge, IL, American Academy of Orthopedic Surgeons, 1989, pp 3-13.
12. Calandruccio JH, Jobe MT: Arthroplasty of the thumb carpometacarpal joint. *Semin Arthroplasty* 1997;8(2):135-147.
13. Tomiano MM, Pellegrini VD Jr, Burton RI: Arthroplasty of the basal joint of the thumb: Long-term follow-up after ligament reconstruction with tendon interposition. *J Bone Joint Surg* 1995;77A:346-355.
14. Foliant EE: Swanson silicone finger joint implants. A review of the literature regarding long-term complications. *J Hand Surg* 1995;20A:445-449.