

# Gouty Tenosynovitis of the Distal Biceps Tendon Insertion Complicated by Partial Rupture: First Case and Review of the Literature

HAND  
1–5  
© American Association for  
Hand Surgery 2016  
DOI: 10.1177/1558944715627639  
hand.sagepub.com

Rick J. Fairhurst<sup>1</sup>, Arnold M. Schwartz<sup>2</sup>, and Leo M. Rozmaryn<sup>1</sup>

## Abstract

**Background:** Given the appreciable prevalence of gout, gout-induced tendon ruptures in the upper extremity are extremely rare. Although these events have been reported only 5 times in the literature, all in patients with a risk factor for or history of gout, they have conspicuously never been diagnosed in the shoulder or elbow. **Methods:** A 45-year-old, right-hand-dominant man with a history of gout presented with pain in his right anterior elbow and weakness in his forearm after a trivial injury. **Results:** Here, we report the first case of gouty tenosynovitis of the distal biceps tendon insertion complicated by partial rupture, a composite diagnosis supported by both intraoperative and histological observations. **Conclusions:** In patients who are clinically diagnosed with biceps tendon rupture and have a history of gout, it is important to consider the possibility of a gout-related pathological manifestation causing or simulating tendon rupture.

**Keywords:** biceps, tendon, rupture, gout, tenosynovitis

## Introduction

Complete and partial tears of the distal biceps tendon are common occurrences, usually due to an eccentric load on the elbow and forearm with the elbow flexed and supinated. Although complete ruptures usually require surgical repair, partial ruptures can be treated conservatively at first but may eventually need operative repair.<sup>1</sup> Such ruptures occur more commonly in males above 30 years of age, smokers lacking tendon nutrition, and individuals taking corticosteroids. In general, however, no obvious predisposing cause for the rupture can be discerned.<sup>7</sup> Distal biceps tendon ruptures are rarely caused by underlying medical conditions.

Gout is a metabolic abnormality caused by the deposition of uric acid, which can form needle-like crystal deposits in soft tissues and joints, and is usually—but not always—seen in individuals with elevated plasma urate levels.<sup>2</sup> It is a systemic disease that may present as an inflammatory deposition arthropathy, soft tissue masses, or both. Kidney involvement includes uric acid lithiasis. Tophaceous deposits can form in any soft tissue or visceral organ, and deposition is favored by biochemical and physical conditions including urate concentration and solubility, pH, temperature, connective tissue structure and ground substance (ie, mucopolysaccharide) matrix material, and

crystal metabolic turnover.<sup>2</sup> The most prevalent sites for tophi are the first metatarsal-phalangeal joint (great toe) and the pinna of the ear, due to their lower body temperature and connective tissue ground substance.

The deposition of urates in tissue induces a prominent inflammatory response that may simulate acute septic arthritis. Established tophi show a histiocytic and foreign body giant cell response in a granulomatous-like pattern surrounding the deposited crystals, and the acute gouty attack shows a neutrophil exudate. Tophi may also be present in ligaments and tendons. The complication of gout-induced tendon rupture occurs mostly in the lower extremities, typically affecting the great toe and ankle. Gouty manifestations in the upper extremity are much less common and can include subcutaneous tophi, arthritis, tenosynovitis, and nerve entrapment.<sup>8</sup>

Gout-induced tendon rupture in the upper extremity is rare, being reported only 5 times in the hand or wrist but

<sup>1</sup>The Orthopaedic Center, Rockville, MD, USA

<sup>2</sup>George Washington University, Washington, DC, USA

### Corresponding Author:

Leo M. Rozmaryn, The Orthopaedic Center, 9711 Medical Center Drive, #201, Rockville, MD 20850, USA.  
Email: leohanddoc@yahoo.com

never in the elbow or shoulder. Here, we report the first case of gouty tenosynovitis causing rupture of the distal biceps tendon.

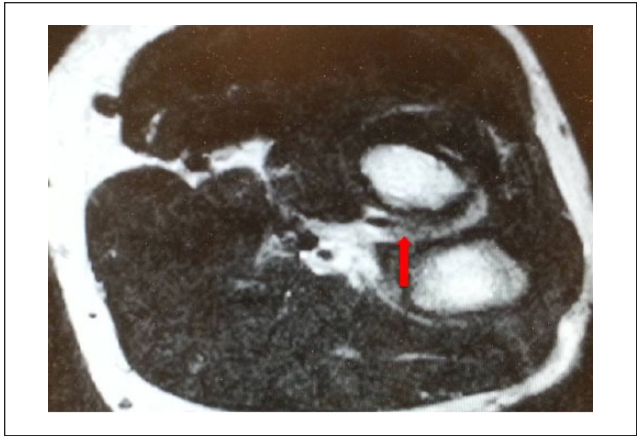
## Case Report

A 45-year-old, right-hand-dominant man with a history of gout, treated with allopurinol, presented with pain in his right elbow and weakness in his forearm after feeling a sudden “pop” while lifting a partition. The pain increased with attempted elbow flexion and forearm supination. He had ecchymosis and swelling extending to the hand. He reported no numbness, tingling, fevers, or chills. Significant medical history included surgical reconstruction of a gouty-infiltrated anterior cruciate ligament several years prior. There was no history of renal disease, smoking, or alcoholism, and no family history of gout. Blood tests revealed no hyperuricemia, evidence of renal disease, or bacteremia.

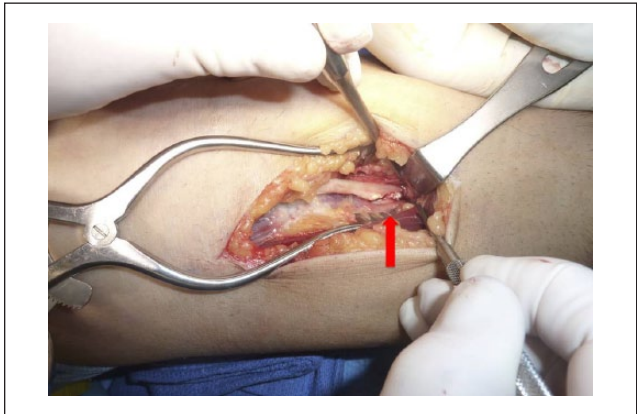
On physical examination, he had olecranon bursitis with marked posterior elbow tenderness and erythema. There was weakness and pain with elbow flexion and supination. Although swollen, his hand exhibited full range of motion without pain. “Hook” test was positive for pain, but the biceps tendon appeared to be in continuity. The x-ray film of the elbow showed calcifications in the posterior elbow. Magnetic resonance imaging (MRI) of the elbow (Figure 1) showed partial tear of a thickened biceps tendon adjacent to its radial tuberosity insertion and a fluid collection around the insertion. At this time, the patient was tentatively diagnosed with a partial biceps tendon rupture.

After 6 weeks of elbow brace immobilization, his arm remained painful with very limited use. Thus, the patient underwent an olecranon bursectomy and an anterior distal biceps tendon exploration. Intraoperative inspection revealed a gouty biceps tenosynovitis at the tendon insertion site, bathed in a clear exudate with 70% tendon rupture of the biceps head (Figure 2). The tendon was completely detached from its insertion at the radius and substantially infiltrated with gouty tophus (Figure 3). The tendon end was debrided and reinserted into the bicipital tuberosity of the radius using an “endobutton” technique. Intraoperative cultures were negative. Postoperatively, the patient was placed into an IROM™ (incremental range of motion) elbow brace fixed at 90°, and after 3 weeks, a progressive range-of-motion program was started. At 7 weeks, a strengthening program was started.

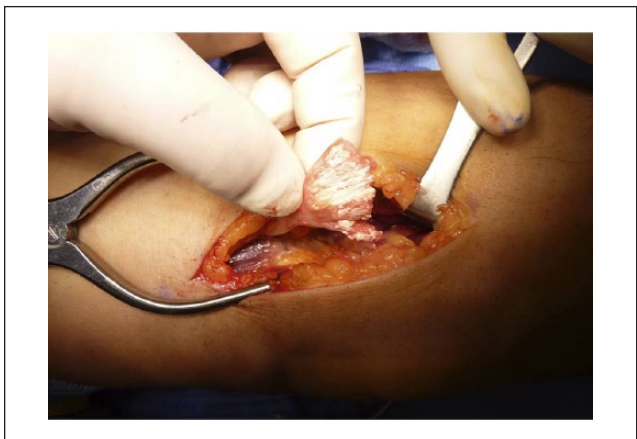Microscopic examination of the tenosynovium showed diffuse replacement of normal tendon architecture with mass-like nodules of tophi (Figure 4). The tophi were composed of a palisading inflammatory pattern of mononuclear cells, histiocytes, and multinucleated foreign body giant cells around a crystalline precipitation. The chronicity of the process was appreciated by the generation of a thick



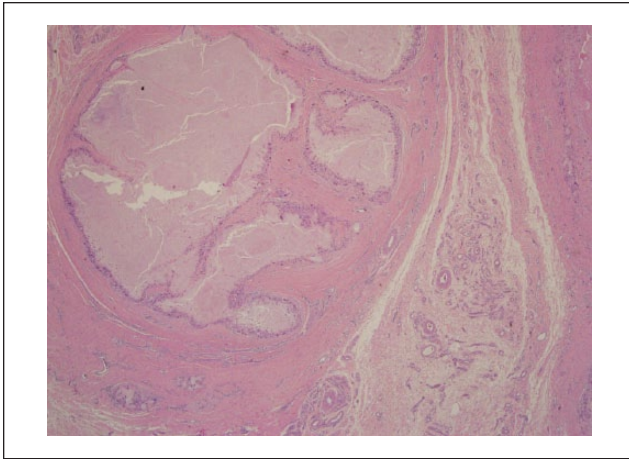
**Figure 1.** Axial MRI image of the distal biceps insertion. Note. Note the partial rupture of tendon at its insertion into the radius and surrounding tenosynovitis. MRI, magnetic resonance imaging.



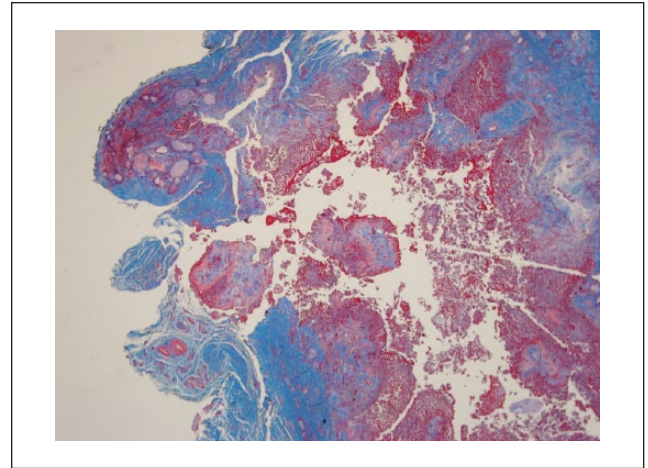
**Figure 2.** Partial (70%) rupture of the distal biceps insertion. Note. Note the gouty infiltration at the tendon end.



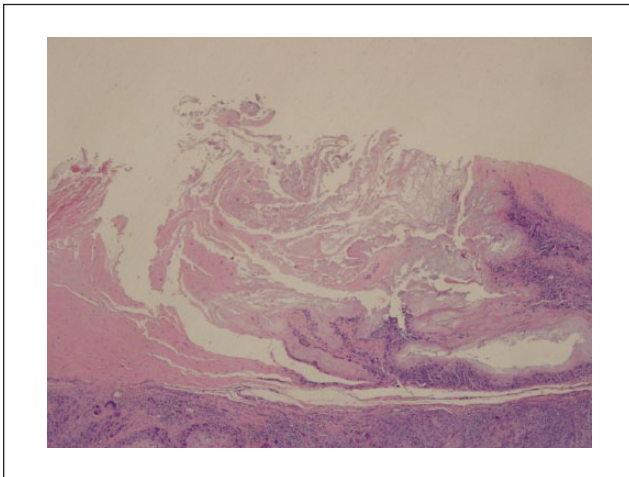
**Figure 3.** Terminal biceps tendon detached. Note. The tendon end is completely infiltrated with gouty tophus.



**Figure 4.** Nodular gouty tophus with fibrous capsule embedded within tendon (hematoxylin-eosin, original magnification  $\times 4$ ).



**Figure 6.** Masson trichrome of active tophaceous deposition with fibrinoid exudate and fragmentation in area of tendon lysis (Masson trichrome, original magnification  $\times 4$ ).



**Figure 5.** Gouty deposition within region of tenosynovial degeneration changes characterized by edematous myxoid matrix and reactive proliferative cellular clones (hematoxylin-eosin, original magnification  $\times 4$ ).

Note. The active urate deposits have a surrounding inflammatory infiltrate.

fibrous capsule around some of the tophi. The tophaceous deposits tended to favor the location of degenerative changes within the tenosynovium that were marked with altered matrix mucopolysaccharide changes, increased interstitial edema, and an attempt at reparative cellular proliferation (Figure 5). Some areas of the degenerative changes were accompanied by lytic and cystic changes.

The pathology of our case also demonstrated active tophaceous deposits with an acute fibrinous exudate and connective tissue lysis. This process eroded through normal tendinous connective tissue and caused rupture of the tendon, best appreciated with the trichrome stain (Figure 6).

The destruction of the connective tissue by the inflammatory cells of the gouty tophus was identified as lysis of collagen and reticulin by the inflammatory process. In summary, the pathology sections illustrated tophaceous deposition within tendinous degenerative changes, accompanied by alteration of matrix material. They also showed lytic and cystic degradation of connective tissue, with fibrinous exudation within active tophaceous deposits leading to tendon rupture.

## Discussion

Here, we report the first case of gouty tenosynovitis leading to distal biceps tendon rupture. Only 5 similar cases where gout is the underlying condition causing or simulating tendon rupture in the upper extremity have been reported in the literature (Table 1). Moore and Weiland<sup>6</sup> presented a 43-year-old man with a long history of gout involving the foot, wrist, and ear who experienced severe burning of his wrist especially at night. Internal neurolysis was performed and tophaceous deposits were observed within the carpal tunnel. Four years later, total infiltration and partial rupture of the extensor pollicis longus (EPL) tendon were observed. Wurapa and Zelouf<sup>9</sup> described a 57-year-old man with a complicated medical history, including gout, who experienced spontaneous loss of index finger flexion. Surgical exploration revealed gouty degradation and rupture of the flexor digitorum profundus (FDP) and the flexor digitorum superficialis tendons. Hung et al<sup>4</sup> reported a 65-year-old man with an extensive gout history and spontaneous painful swelling of the radial dorsal wrist. Surgical examination found rupture of the EPL involving gouty infiltration, with white urate crystals within and around the tendon. Iwamoto et al<sup>5</sup> presented a

**Table I.** Reported Cases of Gouty Tenosynovitis Complicated by Tendon Rupture in the Upper Extremity.

	Year	Age	Sex	Clinical presentation	Ruptured tendon	Gout history	Gout risk factor	Reference
I	1985	43	M	Severe dorsal wrist pain and inability to extend thumb. No history of trauma.	Extensor pollicis longus	Yes	NR	6
II	2002	57	M	Loss of right index DIP and PIP joint flexion. No history of trauma.	Flexor digitorum profundus and superficialis	Yes	NR	9
III	2005	65	M	Loss of left thumb extension. No history of trauma.	Extensor pollicis longus	Yes	NR	4
IV	2010	54	F	Loss of right ring finger extension. History of trauma not reported.	Extensor digitorum communis, multiple	Yes	NR	5
V	1984	28	M	Stiff, swollen left small finger. History of blunt trauma.	Superficialis and profundus	NR	Hyperuricemia	3

Note. NR, not reported; DIP, distal interphalangeal; PIP, proximal interphalangeal.

54-year-old woman with a 3-year history of a painless subcutaneous mass in the dorsum of her hand, an inability to extend her ring finger, and weakness in extending her index finger. Surgical exploration of the wrist exposed hypertrophic crystalline deposits surrounding the extensor digitorum communis and extensor indicis proprius tendons, with rupture of both. Finally, Hankin et al<sup>3</sup> reported a 28-year-old hyperuricemic man presenting with “apparent” rupture of the FDP tendon after sustaining a crush injury. On operative exploration, however, only gouty infiltration of the tendon’s fibrous synovial sheath and adhesions between contiguous structures were observed.

The pathologic mechanism of injury and rupture appears to be due to the deposition of urate crystals within tendinous connective tissue, associated with age-related and possibly trauma-related degenerative changes of tissue structure and matrix material.<sup>2</sup> Deposition and progression of crystal precipitation may be related to nucleation factors, including the fragmentation of collagen and/or matrix material (eg, proteoglycans and chondroitin sulfates). The inflammatory response to urate deposits is associated with connective tissue damage accompanied by collagen lysis and cystic changes. Inflammatory compromise of connective tissue integrity, loss of tendon tensile strength, and fibrinous exudation of active tophi may lead to tendon tears and rupture.

## Conclusion

Considering the prevalence of gout, it is intriguing that so few cases of gouty tendon infiltration have been reported. Interestingly, gouty infiltration of the distal biceps tendon has never been reported in the literature. In this case, we believe that gouty infiltration was the proximate cause of

this patient’s partial rupture and that this etiology should be considered in the differential diagnosis of biceps tendinitis and rupture in patients with a history of gout.

## Ethical Approval

This study was approved by our institutional review board.

## Statement of Human and Animal Rights

This article does not contain any studies with human or animal subjects.

## Statement of Informed Consent

Informed consent was obtained when necessary.

## Declaration of Conflicting Interests

The authors declared no potential conflicts of interest with respect to the research, authorship, and/or publication of this article.

## Funding

The authors received no financial support for the research, authorship, and/or publication of this article.

## References

1. Bain GI, Johnson LJ, Turner PC. Treatment of partial distal biceps ruptures. *Sports Med Arthrosc*. 2008;16:154-161. doi:10.1097/JSA.0b013e318183eb60.
2. Choi HK. Epidemiology, pathology, and pathogenesis. In: Klippel JH, Stone JH, Crofford LJ, White PH, eds. *Primer on the Rheumatic Diseases*. 13th ed. New York, NY: Springer; 2008:250-257.
3. Hankin FM, Mayhew DE, Coapman RA, Snedden M, Schneider LH. Gouty infiltration of a flexor tendon simulating rupture. *Clin Orthop Relat Res*. 1985;194:172-175.

4. Hung JY, Wang SJ, Wu SS. Spontaneous rupture of extensor pollicis longus tendon with tophaceous gout infiltration. *Arch Orthop Trauma Surg.* 2005;125:281-284. doi:10.1007/s00402-004-0670-9.
5. Iwamoto T, Toki H, Ikari K, Yamanaka H, Momohara S. Multiple extensor tendon ruptures caused by tophaceous gout. *Mod Rheumatol.* 2010;20:210-212.
6. Moore JR, Weiland AJ. Gouty tenosynovitis in the hand. *J Hand Surg Br.* 1985;10:291-295.
7. Safran MR, Graham SM. Distal biceps tendon ruptures: incidence, demographics, and the effect of smoking. *Clin Orthop Relat Res.* 2002;404:275-283.
8. Tang CY, Fung B. The last defence? surgical aspects of gouty arthritis of hand and wrist. *Hong Kong Med J.* 2011;17:480-486.
9. Wurapa RK, Zelouf DS. Flexor tendon rupture caused by gout: a case report. *J Hand Surg Br.* 2002;27:591-593. doi:10.1053/jhsu.2002.34312.