

Central Slip Tenotomy With Distal Repair in the Treatment of Severe Chronic Mallet Fingers

Leo M. Rozmaryn, MD

The author is unaware of any studies that combine central slip tenotomy with a distal repair, using small transverse incisions at the proximal interphalangeal and distal interphalangeal joints, respectively, to repair chronic mallet fingers whose deformities exceed 36°. This article describes the technique in detail, as well as its indications, postoperative management, and complications. An illustrative review of a case series follows. (*J Hand Surg Am.* 2014;39(4):773–778. Copyright © 2014 by the American Society for Surgery of the Hand. All rights reserved.)

Key words Central slip tenotomy, chronic mallet fingers.

A SIMPLE, ECCENTRIC AXIAL LOAD to the tip of the finger, causing the distal interphalangeal (DIP) joint to forcefully hyperflex, can disrupt the continuity of the insertion of the conjoined lateral band onto the dorsal aspect of the distal phalanx. With the flexor digitorum profundus tendon unopposed, the tip will assume a flexed posture. Initially thought to be a “jammed finger” by the patient, it is given minor importance and is frequently ignored. The characteristic flexed posture of the distal phalanx may manifest after several weeks, once the swelling has subsided.

Usually, patients seek medical attention within 2 to 3 weeks, and they will be treated nonsurgically. Others will wait up to 3 or 4 months after the full extent of the disability becomes manifest, such as DIP joint pain, erythema, skin breakdown, and difficulty in navigating tight spaces, such as a back pocket. Alternatively, there are patients who have undergone conservative treatment for 3 to 4 months, only to find that the flexion deformity has persisted or recurred. In those patients, there has been weak or incomplete reattachment of the tendon end back to bone, and the

connection may be nothing more than a thin, transparent scar bridge, with the tendon having retracted more than 3 mm.¹ This proximal retraction of the extensor hood causes increased tension on the central slip attachment on the middle phalanx, causing proximal interphalangeal (PIP) joint hyperextension, often with difficulty initiating PIP joint flexion and a snapping sensation.

Early studies advocated no treatment because it was thought that all efforts were futile, and the deformity was not disabling to most patients.² More recently, a plethora of procedures have been proposed, all reporting varying degrees of success long-term. They include scar excision and direct repair to bone,³ scar plication,⁴ tenodesis,⁵ tendon grafting,⁶ spiral oblique retinacular ligament procedure,⁷ Fowler central slip tenotomy,⁸ and DIP arthrodesis at 15° flexion.⁹ Nevertheless, efforts at reattachment of the tendon end alone with and without skin excision largely have met with failure.¹⁰

Fowler central slip tenotomy is a reliable technique for reducing the degree of flexion deformity at the DIP joint, but it has generally not been advocated in deformities greater than 36°. There have been concerns about injury to the triangular ligament and subsequent development of extensor lag at the PIP joint and frank boutonniere deformity. In addition, classic articles on central tenotomy by Harris, Fowler, and others¹¹ advocated a large midlateral approach, sectioning the transverse retinacular ligament, lifting the extensor mechanism, and releasing the central slip from below.

From the Orthopaedic Center, PA, Rockville, MD.

Received for publication January 28, 2014; accepted in revised form January 29, 2014.

No benefits in any form have been received or will be received related directly or indirectly to the subject of this article.

Corresponding author: Leo M. Rozmaryn, MD, The Orthopaedic Center, PA, 9711 Medical Center Drive, #201, Rockville, MD 20850; e-mail: leohanddoc@yahoo.com.

0363-5023/14/3904-0030\$36.00/0
<http://dx.doi.org/10.1016/j.jhsa.2014.01.040>

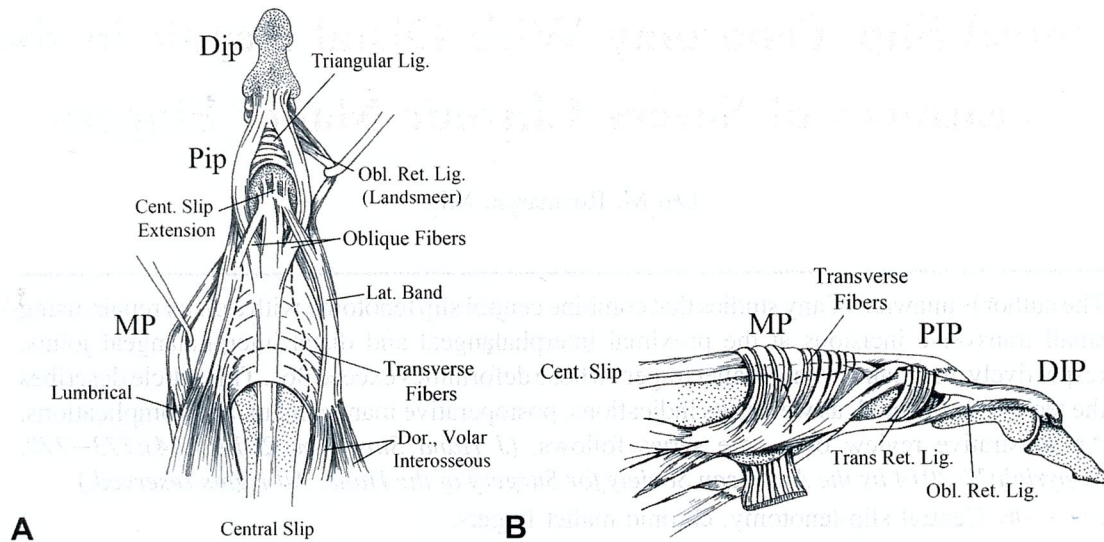


FIGURE 1: **A** Posteroanterior view of the extensor mechanism. **B** Lateral view of the extensor mechanism. Triangular Lig., triangular ligament; Obl. Ret. Lig., oblique retinacular ligament; Cent. Slip, central slip; Lat. Band, lateral band; MP, metacarpophalangeal; Dor., dorsal.

The author is unaware of any studies that combine central slip tenotomy with a distal repair, using small transverse incisions at the PIP and DIP, respectively, to repair chronic mallet fingers, whose deformities exceed 36° . This article describes the technique in detail, as well as its indications, postoperative management, and complications. An illustrative review of a case series follows.

SURGICAL ANATOMY AND KINETICS

The terminal extensor tendon is a flat, thin structure measuring on average 1.1 mm; it inserts onto the distal phalanx up to 1.2 mm distal to the joint margin and 1.4 mm proximal to the germinal nail matrix. The terminal extensor tendon adheres to the underlying dorsal aspect of the DIP joint capsule. The terminal tendon is formed by the confluence of the radial and ulnar lateral bands. Just proximal to this confluence lies a thin membrane that runs transversely between the lateral bands, called the triangular ligament. These prevent volar subluxation of the lateral bands. Injury to this ligament can result in the formation of a boutonniere deformity. The oblique retinacular ligament (Landsmeer) consists of thin fibers that run deep and volar to the lateral bands; they coordinate PIP and DIP flexion and extension. They originate from the lateral flexor sheath and form the outer margin of the terminal extensor tendon at the DIP joint.

The lateral bands are continuations of the interosseous and lumbrical tendons that run along the sides of the digit at the proximal phalanx. Dorsal subluxation of

the lateral bands such as is seen in swan neck deformities is prevented by the transverse retinacular ligaments that run from the flexor tendon sheath dorsally to the volar rim of the lateral bands.

The central slip tendon is a continuation of the extensor digitorum communis to the finger and runs up the middle of the proximal phalanx. It connects to the lateral bands via the transverse fibers and, more distally, through oblique fibers that connect to the lateral bands^{12,13} (Fig. 1).

Schweitzer and Rayan¹ found that the excursion of the terminal extensor tendon at the DIP joint was 1 to 2 mm when the joint was moved passively from full extension to full flexion. They also found that the PIP joint angle of flexion had a significant influence on the degree of possible DIP joint flexion. If the PIP was flexed 90° , the maximal DIP flexion was 82° , whereas if the PIP was extended, the maximal DIP flexion possible was 51° . When the terminal tendon was sectioned via Z lengthening, 1 mm of lengthening allowed 25° flexion. Two millimeters of lengthening allowed 36° . Three millimeters of lengthening allowed 49° and 4 mm of lengthening allowed 63° flexion. Those authors also found variation between the fingers, with the middle finger flexing the most for each millimeter of terminal tendon lengthening. They showed that when the cut tendon end retracted more than 1 mm proximally, it was extremely difficult to approximate the tendon end to its insertion. These data illustrate what occurs when the terminal extensor tears and retracts, allowing the DIP joint to develop an extensor lag that persists even after the gap between the tendon

end and bony insertion is bridged by a scar, and form the basis of the conservative treatment of these injuries.

Chao et al¹⁴ demonstrated in an experimental model that after sectioning the terminal extensor and creating a lengthening of about 3 mm, an extensor lag of 45° was created. When a central slip tenotomy was performed in their specimens, they noted an immediate correction of 37° to 9°. Based on Schweitzer and Rayan,¹² that would represent a proximal migration of 2 mm. They concluded that correction greater than 36° was not possible using this technique, although older studies noted corrections of up to 60°. This could be partly because of remodeling of the terminal tendon. There may be no apparent correction immediately in the operating room under anesthesia, but correction of the DIP extensor lag can continue to improve up to 1 year, something that the experimental model could not duplicate.¹⁵ In an experimental cadaver model, Hiwatari et al created mallet finger deformities by terminal tendon elongation. They then detached the central slip and the lateral band from the middle phalanx by one-third, one-half, and two-thirds of the phalangeal length of the middle phalanx, and they measured the extensor length of the DIP and PIP joint before and after this procedure. After distal sectioning, the extensor leg was 44°. After central slip and lateral band detachment of one-third of the phalangeal length, the residual leg of the DIP joint was 19°. With the one-half detachment, the length was 13°. With two-thirds detachment, the average leg was 6°. There was minimal extensor lag at the PIP joint. Thus, the amount of correction can vary with the degree of central slip tenotomy, something that was not considered in the literature.¹⁶ From these articles, we can see that full correction of the extensor lag was less consistent with greater degrees of preoperative flexion deformity. The question thus remains whether an ancillary procedure should be done on the extensor mechanism after a central slip tenotomy when the presenting extensor lag at the DIP joint exceeds 40°.

INDICATIONS

The technique proposed in this article is a central slip tenotomy followed by terminal extensor reefing (without excision of the bridging scar) and by securing the reefed scar and tendon end to the distal phalanx insertion, by means of bioabsorbable bone anchors.

Indications for surgery include a mallet finger of more than 4 months' duration, because the patient either presented late or failed a 4-month course of

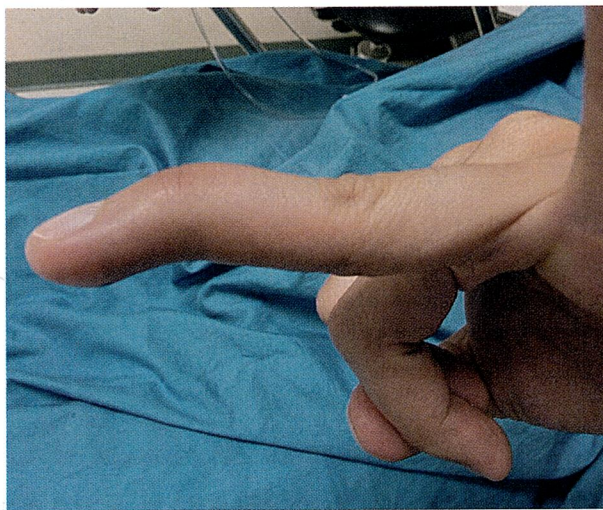


FIGURE 2: Preoperative appearance of the finger after 4 months of conservative therapy. The DIP joint is at 45° flexion and the PIP joint is at 25° hyperextension.

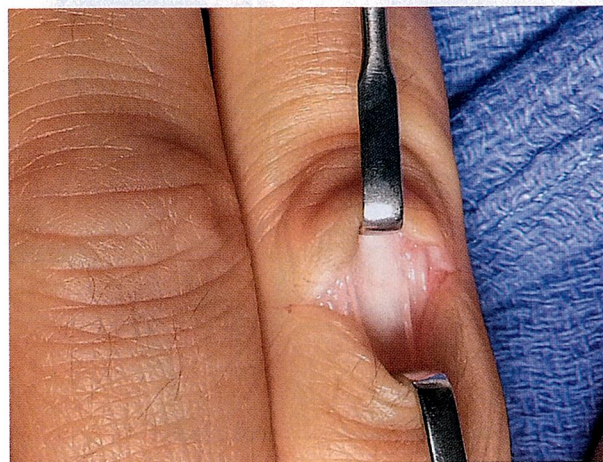


FIGURE 3: Transverse incision 6 mm proximal to the PIP joint.

conservative treatment; an initial injury that required skin closure only; and no specified upper limit of DIP flexion deformity.

Contraindications include DIP or PIP joint contracture; primary swan neck deformity in which the pathology is primarily at the PIP joint; and extreme preoperative joint hyperextension, because greater than 25° preoperative hyperextension has not been reported previously for correction with this technique. It is generally recommended that for greater hyperextension of the PIP joint, a spiral oblique retinacular ligament or Thompson procedure be contemplated.^{7,8} Other contraindications include unstable skin cover over the dorsum of the DIP joint, degenerative joint disease at the DIP joint, and intra-articular fracture involving the DIP joint.

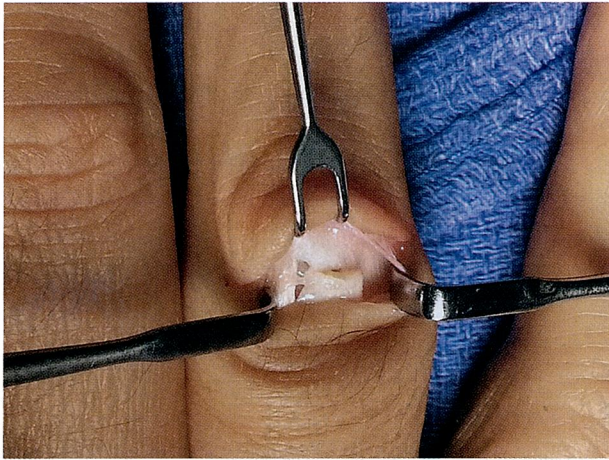


FIGURE 4: Two longitudinal cuts made at the junction between the central slip and sagittal bands, staying 6 mm proximal to the PIP joint line.

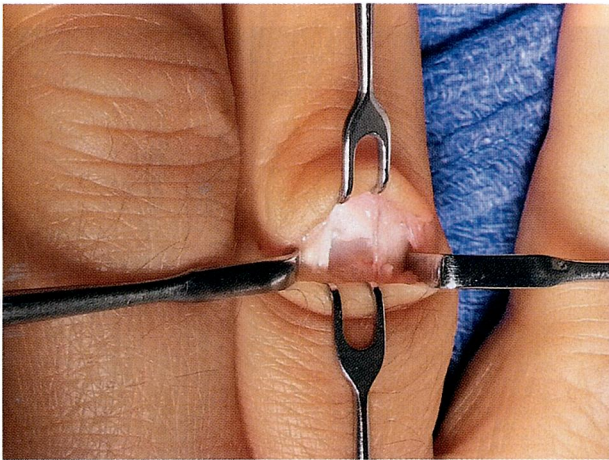


FIGURE 5: The segment of tendon 3 × 6 mm is removed. Care is taken to stay proximal to the PIP joint and avoid the lateral bands.

SURGICAL TECHNIQUE

Figure 2 shows the preoperative appearance. Surgery is done under regional anesthesia. The PIP joint and DIP joint are manipulated through a full range of motion and any contractures are stretched out, most commonly a DIP joint flexion-contracture.

A transverse incision is made across the dorsum of the proximal phalanx 6 mm proximal to the PIP joint line. After obtaining hemostasis, the extensor hood is identified, and the margins between the central slip fibers and the lateral bands are identified by their varying direction of fibers. The lateral bands are oblique to the long axis of central slip fibers (Fig. 3).

Two longitudinal cuts are made at the junction about 4 mm long and the width of the central slip, typically between 3 and 6 mm wide and 6 mm long

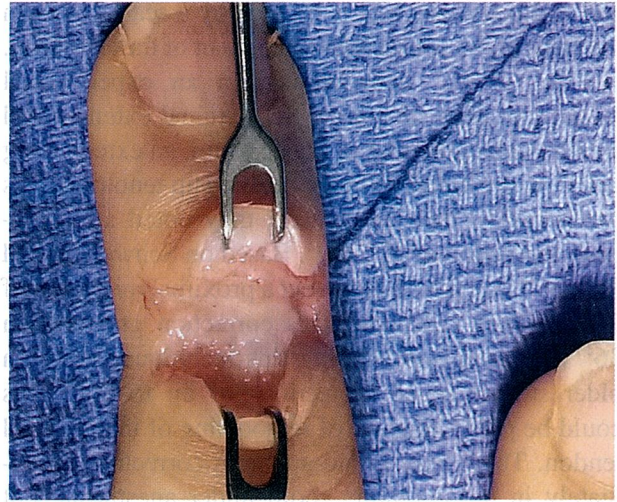


FIGURE 6: Retracted terminal extensor tendon with a scar bridge. Note the demarcation between the striated extensor tendon and the amorphous scar. The terminal extensor is retracted 3 mm.

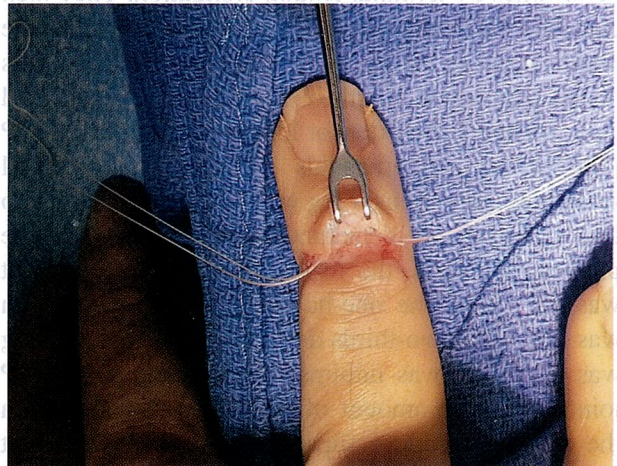


FIGURE 7: Two suture anchors are placed into the distal phalanx. Care is taken not to drill into the germinal nail matrix.

(Fig. 4). Care is taken to stay more than 5 mm proximal to the PIP joint to avoid injuring the triangular ligaments. The segment of tendon is removed (Fig. 5). The PIP joint is taken through a full passive range of motion. In many cases, one can see an immediate correction in the flexion attitude of the DIP joint of 50%, but it cannot be counted on to occur consistently. The PIP joint typically goes into a 5° extension lag but corrects to neutral, once the patient starts to strengthen the digit.

After skin closure, if there is residual contracture, a transverse skin incision is made over the DIP joint. The terminal tip of the extensor tendon is usually retracted 2 to 3 mm and is clearly demarcated from the bridging scar by its bright yellow color. The bridging scar is gray and transparent (Fig. 6).

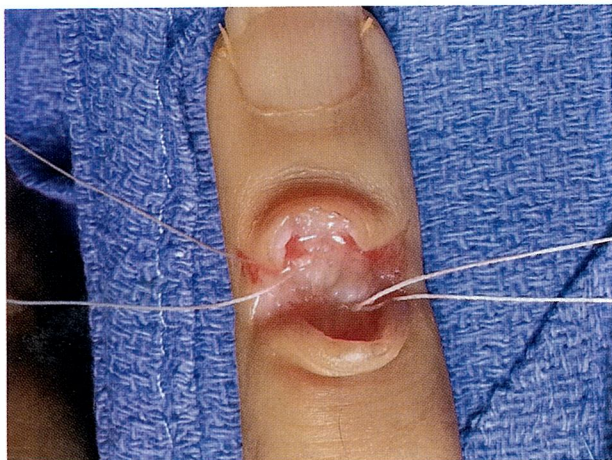


FIGURE 8: Multiple cruciate locking horizontal sutures are passed through the scar and terminal tendon and tightened until the DIP joint assumes a neutral position against gravity.

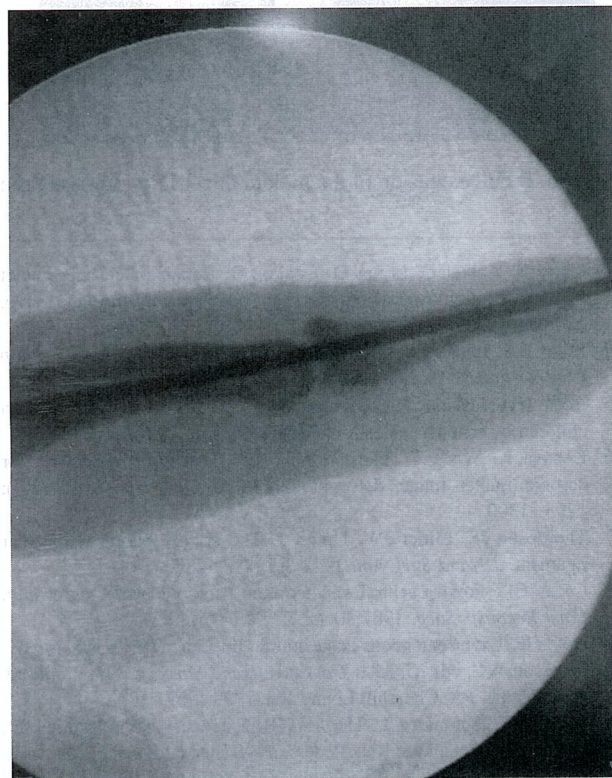


FIGURE 9: Postoperative x-ray. The DIP joint is pinned into neutral.

Five millimeters beyond the DIP joint, 2 micro bioabsorbable suture anchors are drilled into the distal phalanx. Care is taken not to breach the germinal nail matrix (Fig. 7). Cruciate locking horizontal mattress sutures are placed into and beyond the bridging scar into the tendon end. Care is taken not to detach the tendon from the scar. Successive passes with the suture are made until the DIP joint reduces

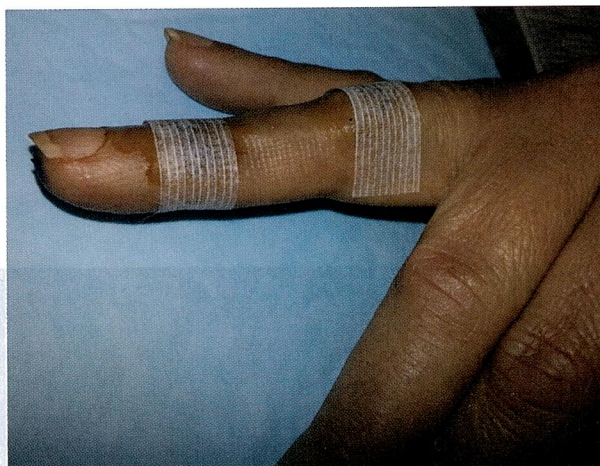

FIGURE 10: Postoperative appearance of the finger. Note the 5° extensor lag at the PIP joint.

back to full extension against gravity (Fig. 8). A 0.9-mm (0.035-in) Kirschner wire is passed from distal to proximal under x-ray control from the fingertip through the DIP joint into the distal condyles of the middle phalanx to hold the reduction (Fig. 9). The DIP joint is hyperextended about 5°. The Kirschner wire is cut just above of the skin, and skin closure is routine.

POSTOPERATIVE REGIMEN

The finger is protected in a bulky dressing and a volar splint in about 25° flexion of the PIP joint for 10 to 14 days. The sutures are then removed (Fig. 10) and the finger is placed into a finger cast immobilizing the DIP joint only for 2 additional weeks. At 4 weeks, the pin is removed and full active range of motion commences at the DIP joint. The PIP joint can undergo full active and passive range of motion. Passive range of motion at the DIP joint is discouraged, because it may cause a recurrence of the flexion deformity. Maximal range of motion of both joints is typically obtained by 6 months (Fig. 11).

COMPLICATIONS

Apart from the generic list of potential complications such as pin track infection, pin breakage, and wound infection, there are potential complications specific to the technique:

- Incomplete correction
- Recurrent flexion deformity, usually caused by postoperative passive flexion stretch of the DIP joint
- Extensor lag at the PIP joint from excessive resection of tendon including the lateral bands

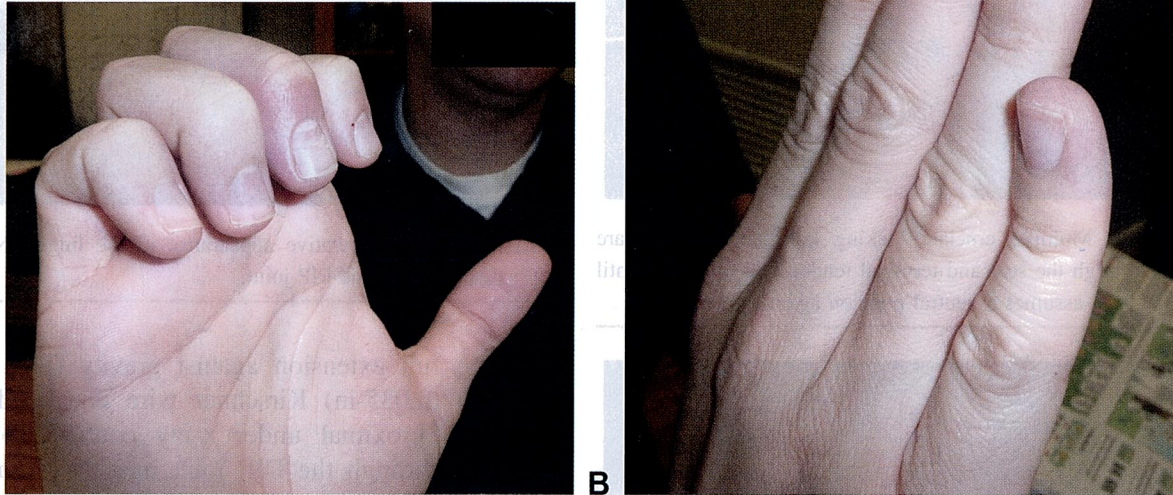


FIGURE 11: A At 1 year, flexion of the middle finger DIP joint is near normal. **B** Full extension of the middle finger DIP joint has been achieved at 1 year. Note the full extension at the PIP joint.

- PIP joint stiffness caused by excessive immobilization
- Skin breakdown over the DIP joint from bulging knots, requiring secondary exploration and removal
- Nail deformity from distal placement of the drill holes

One can avoid most of these by meticulous attention to detail and close monitoring of patients during their rehabilitation.

CASE SERIES

From 2002 to 2012, 39 patients underwent central slip tenotomies. The time to surgery ranged from 2 to 24 months, with an average of 4.8 months. Preoperative DIP joint extensor lag ranged from 15° to 80°, with an average of 45°; PIP joint hyperextension ranged from 0° to 70°, with an average of 18°. At an average of 4.1-month follow up, DIP joint extensor lag ranged from 0° to 30°, with an average of 6.7°; PIP joint residual hyperextension deformity ranged from 0° to 30°, with an average of 4.8°.

REFERENCES

- Schweitzer TP, Rayan GM. The terminal tendon of the digital extensor mechanism: part II, kinematic study. *J Hand Surg Am.* 2004;29(5):903–908.
- Moss JG, Steingold RF. The long term results after mallet finger injury: a retrospective study of one hundred cases. *Hand.* 1983;15(2):151–154.
- Ulkur E, Acikel C, Ergun O, Celikoz B. Repair of chronic mallet finger deformity using Mitek micro arc bone anchor. *Ann Plast Surg.* 2005;54(4):393–396.
- Elliot RA. Injuries to the extensor mechanism of the hand. *Orthop Clin North Am.* 1970;1(2):83–89.
- Boek HD, Jaekenn RR. Treatment of chronic mallet deformity in children by tenodesis. *J Pediatr Orthop.* 1992;12:351–354.
- Kanaya K, Wada T, Yamashita T. The Thompson procedure for chronic mallet finger deformity. *J Hand Surg Am.* 2013;38(7):1295–1300.
- Thompson JS, Littler JW, Upton J. The spiral oblique retinacular ligament. *J Hand Surg Am.* 1978;3(5):482–487.
- Lucas GL. Fowler central slip tenotomy for old mallet deformity. *Plast Reconstr Surg.* 1987;80(1):92–94.
- Doyle JR. Extensor tendons—acute injuries. In: Green DP, Hotchkiss RN, Pederson WC, eds. *Green's Operative Hand Surgery.* Vol. 2. 4th ed. Philadelphia, PA: Churchill Livingstone; 1999:1962–197.
- Baratz ME, Schmidt CC, Hughes TB. Extensor tendon injuries. In: Green DP, Hotchkiss RN, Pederson WC, eds. *Green's Operative Hand Surgery.* Vol. 2. 5th ed. New York, NY: Churchill Livingstone; 2005:187–218.
- Bowers WH, Hurst L. Chronic mallet finger: the use of Fowler's central slip release. *J Hand Surg Am.* 1978;3(4):373–376.
- Schweitzer TP, Rayan GM. The terminal tendon of the digital extensor mechanism: part I, anatomic study. *J Hand Surg Am.* 2004;29(5):898–902.
- Littler JW. The finger extensor mechanism. *Surg Clin North Am.* 1967;47(2):415–423.
- Chao JD, Sarwahi V, Da Silva YS, Rosenwasser MP, Strauch RJ. Central slip tenotomy for the treatment of chronic mallet finger: an anatomic study. *J Hand Surg Am.* 2004;29(2):216–219.
- Grundberg AB, Reagen DS. Central slip tenotomy for chronic mallet finger deformity. *J Hand Surg Am.* 1987;12(4):545–547.
- Hiwatari R, Kuniyosh K, Aoki M, et al. Fractional Fowler tenotomy for chronic mallet finger: a cadaveric biomechanical study. *J Hand Surg Am.* 2012;37(11):2263–2268.